The Royal London

Ophthalmic Hospital Reports.

Vol. XVI. Part III. October, 1905.

ON HEREDITY IN THE VARIOUS FORMS OF CATARACT.

By E. Nettleship.

The influence of heredity in causing cataract is mentioned by nearly all authors. Many single examples and small collections of cases have been published, more particularly in relation to the various congenital forms, as the list of references at the end of this paper will show. I do not know, however, that any considerable collection of material has been made by any one writer. Daust's Thesis (1899) [45] is one of the richest in cases that I have seen, and contains many references.

The following observations are based upon notes of my own cases, and of a certain number of published ones; but I have not attempted to exhaust the literature of the subject, and many other published records of familial or hereditary cataract might be found. I have purposely omitted reference to some of the very earliest published examples. In my own cases the informant has been, as a rule, a member of the youngest affected generation, and has been counted as having cataract for the purposes of this paper if striæ or vacuoles, however slight, were present in his or her lenses. My own material was obtained for the most part from educated patients, and their testimony on such a well-known condition as cataract may, I believe, nearly always be accepted.

It seems natural to begin by recognising two principal classes of cataract, (A) acquired or post-natal, and (B) congenital.*

The congenital class (B) is subdivided into lamellar, the much less common axial or spindle form, and complete cataract. Under the group of complete congenital cataract may fairly be included all cases of general opacity or opalescence of lens discovered within a few weeks, say two months, of birth, and also the cases in which a shrunken disc of opaque lens is discovered at the age of several months, or perhaps a year.

Class A of acquired—*i.e.*, post-natal—cataract contains, besides the ordinary senile forms, a præsenile or juvenile group in which the opacity comes on at various ages between childhood and about 40. This subdivision is, no doubt, arbitrary, and does not correspond with any differences in the cause or character of the cataract; but it has some practical conveniences.

The cases, often very distinctly marked, of disseminated cortical cataract, so common in young adults, characterised by dots and short blunt striæ, sometimes of blue colour, immediately beneath the capsule, and often least abundant at the anterior pole, are included for the present with the acquired cataracts, the cases being classified according to the patient's age. I do not know whether this form has been proved to be congenital, but all will agree that though the opacity often makes no visible progress for many years, it does occasionally increase to completeness. In certain examples there is great difficulty in distinguishing such cases from true lamellar cataract of slight degree (see Cases 76, No. 3, and 79).

If any important differences exist between the conditions governing inheritance or familial liability in one kind of cataract as compared with another, we may expect, I think,

* It must be admitted that cases are met with from time to time in which we cannot say whether the cataract was present at birth or came on during the years of early childhood.

that the division will correspond with the two main classes A and B.

Class A. ACQUIRED OR POST-NATAL CATARACT.

This consists of about 145 families, containing upwards of 500 affected persons. From 25 to 30 of the 145 pedigrees have been published, and several other very good ones have been given to me by Mr. Lawford, Mr. Fisher, and other friends; the remainder, upwards of 100, are from my own notes. The distribution of the cases was as follows:—

Senile Cataract.—Families, 122. Persons, 375; male, 145; female, 230.

These numbers show 38 per cent. male and 62 per cent. female, or at the rate of 1,536 females for every 1,000 males.

The 122 families are divisible as follows:—

Only one generation (siblings* only) known to have cataract—32 families containing 82 affected persons; 28 male, 54 female.

Two generations known to have cataract—63 families with 152 affected persons; 55 male, 97 female.

Three generations—26 families with 106 affected persons; 44 male, 62 female.

Four generations—4 families with 31 affected persons; 15 male, 16 female.

Five generations—1 family with 7 affected persons; all male.

Præsenile or Juvenile Cataract.—Families 25, persons 152; males 49, females 62; sex not stated, 41.

Only one generation known to have cataract (siblings only), 3 families containing 9 affected persons; 4 male, 5 female.

Two generations known to have cataract—13 families with 35 affected persons; 14 male, 21 female.

* Siblings, see footnote to p. 183.

Three generations—5 families with 38 affected persons; 11 male, 7 female, sex not stated 16.

Four generations—1 family with 12 affected persons; 5 male, 4 female, sex not stated 3.

Five generations—2 families with 40 affected persons; 15 male, 25 female.

Six generations—1 family, 18 cases, sexes given only in part.

The *total of both groups of Class A* gives 146 families with at least 545 persons; male 200, female 305, sex not stated 41.

One generation (siblings only)—35 families, 91 persons; male 32, female 59.

Two generations—76 families, 187 persons; male 69, female 118.

Three generations—31 families, 144 persons; male 55, female 69, sex unstated 16.

Four generations—5 families, 43 persons; male 20, female 20, sex unstated 3.

Five and six generations—4 families, 65 persons; male 22, female 25, sex unstated 18. (But in one of these genealogies (Case 18*a*) records have been kept of only the male members, the question having had reference to family property.)

The above data suggest certain questions from which the following conclusions may be drawn, although it is quite probable that some of them may be upset in future by a larger and more accurate series of records:—

1. When senile cararact occurs in more than one generation it is almost always continuous from one generation to the next (parent to child to grandchild, etc.) and appears very seldom to skip a generation. We must bear in mind, however, that continuous descent may not be so prevalent as it seems, for a cataractous grandchild (and it is from such that nearly all the pedigrees of three generations or more are obtained) would be less likely to hear of cataract in his grandparent if his own parent had been free than if that parent had also been affected. On the other hand, an

ancestor whose sight continued good in spite of some opacities of lens would be reputed by his family to have been free from cataract, and thus seem to break the chain of continuity which in reality he maintained by a feeble link. Collaterals,* uncles, aunts, cousins, are sometimes stated to be affected, and no doubt numerous collateral or indirect cases would be found if the histories were more complete.

In the much smaller group of præsenile and juvenile-acquired cataracts, of which I have found only 20 available pedigrees, yielding 49 childships,† the descent was also continuous in all except 3, in 2 of which the passage was from aunt to niece, whilst in the third (Maunoir's case of 4 generations) there was a break of *direct* descent in the second generation.

We may therefore say provisionally that when cataract, acquired at whatever age, occurs in more than one generation, it descends in the great majority of cases from parent to child, seldom skipping a generation; but that it is not uncommon for collaterals to be also affected.

2. A question allied to the last is whether in each childship the affected siblings occur in succession or are separated by unaffected children?

I have only about 9 *childships of senile cataract* complete enough to be of use in this connection. In 4 of these childships the cataractous children were born in succession, but 3 of these 4 occurred in one and the same pedigree (Heath, Case 19) of 4 generations; the fourth childship was in a pedigree of three generations in which the third generation inherited from both parents. (Case 1.)

* Some authors, *e.g.*, Bollinger, define *collaterals* as children of the same parents (Siblings), and use the terms *indirect* or *lateral* for inheritance from grandparents, uncles, and aunts, *direct* inheritance being from parent to children.

† "Childship;" Dr. E. Stainer's term to express all the children of one parentage. The word Siblings is used in the same sense by Karl Pearson, and though to my ear less euphonious, is sometimes more convenient. I propose to use these terms indifferently.

KEY TO THE SIGNS USED IN THE FOLLOWING PEDIGREES.

♂, *Male unaffected.* ♂, *Male with cataract.*

♀, *Female unaffected.* ♀, *Female with cataract.*

○, *Sex not stated unaffected.* ●, *Sex not stated with cataract.*

◯, *Several Children free from cataract.* When all are of the same sex the sex-sign is added to the circle; numbers, Roman or Arabic, within the circle indicate the number of such children.

Parents joined by a bracket, above or below, are cousins; thus ♂ ♀ or ⌒

Brothers or sisters joined by a horizontal line are twins: thus ♀—♀.

Siblings (Professor Karl Pearson), *Childship* (Dr. E. Stainer).—Synonymous terms indicating the entire offspring of one parentage, used instead of "brothers and sisters;" miscarriages and still-births are included when known.

Siblings when not underlined are in their true order of birth, the first-born being at the left-hand end of the line.

A wavy line (〰) *beneath a childship* means that the order in which the members were born is not known.

Successive generations are indicated by Roman numerals (I, II, III, etc.), or occasionally by letters (A, B, C, etc.), placed at the side of the diagram.

N.B.—In such of the published cases as contain the facts in "tree" form, I have copied the authors' pedigrees, but, for the sake of uniformity, have substituted the signs in the above key. But when, as in the great majority of published cases, no diagrams are given, I have constructed the figures from the authors' statements.

CASE 1 (Fig. 1) (51,171).—Showing continuity and double inheritance of senile cataract.

1. Grandfather had cataract. 2. Son of 1. 3. Wife of 2; both these had cataract; they were not cousins.

4 to 8. Children of 2 and 3, in order of birth.

4. Mr. B., 51,171, cataract diagnosed, æt. 57; when 59, R. was complete, L. incomplete (1899). 5. Operated for cataract with success; still living in 1899. 6. Two sisters; good eyes. 7. Son, died of heart disease. 8. Son, drowned.

Of *childships of Præmature and Juvenile Cataract,* I have found 11 that bear on the point; in at least 7 of them the cataractous children were born in succession. Berry comments on this point in his own case (Case 27, below), and observes that the tendency of the cases of cataract to appear in successive siblings is apparently caused by a greater tendency to transmission by the mother at some particular period of her child-bearing life than at others.* He further noticed that in his case the eldest girl of an affected childship never escaped.

If any conclusion were permissible from such small numbers it would be that when several siblings in succession suffer from acquired cataract, the liability to cataract will be found to have run through several generations, or to have been intensified by inheritance from both parents.

3. Does hereditary acquired cataract descend more frequently through the father or the mother?

In the group of senile cataract I have about 112 instances of transmission from parent to child, using each 2 generations (1st to 2nd, and 2nd to 3rd) separately.

In 67 of these instances the tendency was transmitted through the mother, in 45 through the father, *i.e.,* it descended more often through the mother than through the father in the proportion of about 1,466 mothers to every 1,000 fathers.

I do not attach quantitative value to these figures. In

* Sir William Adams (2*b*) observed as long ago as 1817 that in his experience when *congenital* cataract affected more than one member of a childship, the affected children were always in succession, and he gives two illustrative cases, one of them of three generations (Cases 84 and 91 below).

the first place, the numbers are very small; secondly, we must allow for the greater difficulty experienced, from sundry causes, in obtaining family histories from men and concerning men, than from and concerning women; lastly, a decided preponderance would be expected in women owing to the woman's greater expectancy of life.

Whether these various sources of error do or do not explain the whole of the above stated excessive frequency of hereditary senile cataract in women as compared with men cannot at present be determined; either thesis might be defended.

In this connection we need to compare (1) the sex frequency in hereditary cataract with (2) the sex frequency in similar cataract with no history of heredity; and (3) with the sex frequency at the corresponding ages (say 45 to 85) in the population from which the patients with cataract are drawn. No fair comparison can be made at the present time between any two of the above three terms; the collection of material for deciding No. 1 is only in its infancy; no attempt to decide No. 2 is possible until family histories have been taken by routine in a large series of cases; and as to No. 3, some idea of its complexity may be gathered by an inspection of the Report of the Census of England and Wales for 1901. From this Blue Book we learn that (*a*) the proportion of females to males has gradually increased from 1,036 females to every 1,000 males *of all ages* in 1821, to 1,068 females in 1901; (*b*) that the sex frequency varies widely in different districts of the country, and even in different parts of London, the excess of females being much above the average in some of the southern counties and in London as a whole; (*c*) that between the *ages of* 45 *and* 85 the sex frequency shows similar variations both as to dates and localities; and that in the counties most likely to send their cataract cases to London, and in London itself, the proportional number for women within those ages in 1901 varied between 1,164 and 1,209, say about 1,175.

Even the incidence of senile cataract as a whole in the

two sexes cannot be determined so easily as one would suppose, and no doubt such disturbing factors as those just alluded to will explain many of the widely different statements on this subject that are to be found in literature. In regard to London experience, the following figures may serve as a starting point. I have ascertained the sex in 4,283 persons operated upon for senile cataract during a series of years at Moorfields, St. Thomas's, and St. Bartholomew's Hospitals, and from my own private practice, and find that 2,370 (56 per cent.) were women, and 1,913 (44 per cent.) men, or 1,240 women to 1,000 men. Though a large number of these patients were, of course, from London or the "Home" Counties, a considerable sprinkling came from many different and more distant parts, and as the corresponding proportional numbers for all England and Wales (1,142) and even for the "Home" and London district (say 1,175) are notably less than 1,240, it seems fair to conclude that in our country women are probably somewhat more liable to senile cataract than men, and that this greater liability, together with the woman's greater expectancy of life, may explain the relative frequency of descent of familial cataract through the mother that has been referred to on p. 185.

But if, departing from mere numbers, we examine only the longer pedigrees of senile cataract—of three generations and more—in their entirety, *i.e.*, without taking successive pairs of generations separately (1st to 2nd, 2nd to 3rd, etc.), the relative frequency of descent through the female is very striking. I have 26 available pedigrees of 3 generations or more. In 8 of these the descent was invariably from female to female to female, and in 5 others a female transmitted in nearly every case. In only 4 families did descent occur from male to male to male.

Then I have one case (Case 29) of 2 generations in which the mother, marrying twice, had a cataractous daughter by each husband.

In the præsenile group a similar preponderance of descent

through the mother appears, though the numbers available are small; in 46 instances of transmission, descent was through the mother in 27, through the father in 19.

At this point attention may be drawn to the interesting fact that in certain stocks of senile and præsenile cataract the disease has a special tendency to select one sex to the exclusion of the other: in one stock all, or a marked majority of, the affected persons being males, as in the examples on the following pages; in another stock all or the great majority being females. It seems doubtful whether either sex has a marked preponderance to this tendency, for whilst in 9 such pedigrees all the cases, and in 4 others a majority, occurred in males; in 7 pedigrees all the cases, and in 10 others a majority, were in females. This special liability of one sex or the other to suffer exclusively in certain families is also well illustrated in some of the congenital cases:—thus in Galezowski's "Incomplete lamellar" family (Case 66) 3 generations gave 7 patients all females; whilst in Dyer's case (Case 81) of unknown kind, but not improbably lamellar, cataract occurred only in the males (about 10 cases); Müller's Case (Case 78), and Appenzeller's Case 6 (Case 85 below) both congenital forms, also show this feature. Arago [23] makes the same point when he suggests as a working hypothesis in discussing his own præsenile case (Case 39) that "hereditary cataracts are transmitted by preference to individuals of the same sex as the one first affected;" this is true in some cases, but exceptions are common.

In the following cases nearly all the sufferers were males:—

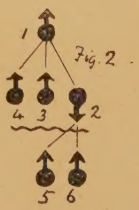

CASE 2 (Fig. 2) (J., 36,179).—Cataract in 6 members of 3 generations, all the cases except 1 being in males.

1. Had cataract.

2. A daughter, born 1818, and operated for cataract when 63 years old. Had 2 sons with cataract (below).

3 and 4. Two brothers of No. 2 who had cataract.

5 and 6. Sons of 2.

5. Mr. J. J. Cataract diagnosed at age of 46.

6. Mr. R. D. J., born 6 years after No. 5. Cataract diagnosed at age of 47; rapidly matured, and was extracted at age of 49, with good result.

CASE 3 (Fig. 3).—Galezowski [21]. Cataract in 4 generations, the first patient being a woman, but all the subsequent ones men.

In Ziem's case (Case 47) of juvenile familial cataract the males suffered in 4 successive generations, but apparently no females were attacked. But in one of Sichel's cases (Case 40 below) in 3 generations females suffered exclusively.

4. Another question—Is hereditary acquired cataract usually transmitted to the same sex or the opposite?

Examination of the senile and præsenile groups together shows that according to my figures the sex of the cataractous subjects remains the same in each succeeding generation in somewhat more than half the cases and changes in rather less than half.

The conclusion from what has been said as to sex in relation to descent in acquired cataract is that after making a large allowance for survival, for imperfection in note-taking and for other sources of error, females are probably somewhat

more liable to familial acquired cataract than males, and that the disease is derived more often from the mother than the father; but that it is transmitted by the predisposed or affected mother to her sons nearly, perhaps quite, as frequently as to her daughters.

5. Another question is whether hereditary senile and præsenile cataract shows a tendency to appear earlier, or at least to mature earlier, or later, or at about the same age, in each succeeding generation? The data for answering this question numerically for the senile group do not exist, but a number of instances illustrating one or another of the above occurrences can be quoted.

The following cases appear to show earlier incidence or "anticipation"* in the younger generation:—Case 2 (p. 189) is a good instance. The following are further examples:—

Case 4 (44,218).—Father, operated for cataract when past 60.

Son, symptoms recognised æt. about 47; complete in one eye æt. 48, when it was operated with good result.

Case 5 (49,101).—Father operated for cataract, æt. 68. Had 8 children.

No. 1, son, both eyes operated for cataract, æt. 49; good result; living, æt. 51.

No. 8, son, cataract began æt. 35; æt. 36 seen with extensive posterior cortical opacities.

Nos. 3 and 6, both sons, died of renal and vascular disease respectively, one being very alcoholic.

Case 6 (39,221).—Father operated for cataract, æt. 50.

Cataract began in son, æt. 35, and nearly complete in one eye at 40.

Case 7 (T. I. P., 1885, 150).—Father, cataract in old age.

One son and two daughters all operated for cataract at or before 50, and all did well.

* "Anticipate;" the term used in describing cases of ague in which the attack begins at an earlier hour in the day than did the attack that immediately preceded it. (Bristowe, Theory and Practice of Medicine, 7th edit., p. 288.) The term may be used in the present connection by substituting years for hours and, for successive attacks, persons of successive generations.

CASE 8.—For this example I have to thank Mr. Lawford :—Thomas R., sight began to fail æt. about 46. When 48 (1903), R. cataract complete, and extracted with good result; L. incomplete. His father had cataracts removed when æt. 70.

CASE 9 (55, 22).—Mother, preliminary iridectomy 1896, when she cannot have been much less than 60, for her daughter was then æt. 40. This daughter also had preliminary iridectomy in 1898, when she was 42.

CASE 10 (50, 123, and 124).—Father, cataract diagnosed in L., æt. 55 : seen, æt. 57, with nuclear haze in L. R. lens clear (June, 1899).

Daughter, æt. 21 at above date, had fine marginal opacities and scattered vacuoles in both lenses.

CASE 11 (45, 111, and 112).—Mother, æt. 53, abundant fine vacuoles and striæ in lower part of each lens, not interfering. V. 6/5.

Daughter, æt. 27, fine dots on back of R. lens, and a single one on back of L. Slight interference with V. for a number of years.

CASE 12 (43, 70, and 46,141).—Mother, cataract diagnosed about 65 ; still very incomplete but increasing æt. 72.

Daughter, striæ and vacuoles, æt. 28.

CASE 13 (14, 33).—Mother's cataract diagnosed when she was æt. between 30 and 40 : progress very slow and not complete 30 years later, when cataract was diagnosed in her son, æt. 39. In this son it became complete in one eye, and advanced in other when he was 42.

CASE 14 (21, 117, and 14,124).—Mother said to have had cataract when quite old, and was blind (of it) for 3 years before she died, æt. 90.

Two daughters, cataract began about 60, and operated by me, æt. 64 and 68.

One daughter, operated long ago for cataract, which came when a girl.

One brother had cataract, æt. about 30 ; was operated, and saw well ; now dead.

One brother, now (1887) æt. 60, blind of cataract for many years and insane.

CASE 15.—Louis Stricker[31] saw double cataract develop in a woman at the age of 57, in her daughter at 48, and in this daughter's daughter at 26.

CASE 16.—Appenzeller[24] mentions (as his Case 8) that cataract formed in a woman at the age of 54, her son became blind of cataract at 35, and in a daughter younger than the affected son cataract began at 24, and became complete in about a year.

In Case 29, early posterior-cortical cataract found in father, æt. 31; in son, æt. 24.

In Case 30, posterior-cortical cataract diagnosed in aunt, æt. 36, but probably then of several years' standing. Similar cataract began in two of her nieces (themselves sisters) at about æt. 8, and became complete soon afterwards.

In Case 31, dotted cortical cataract was diagnosed in the mother, æt. 32, and 9 years later in her daughter, æt. 14; but it was probably present in the daughter at least 5 years before, if not at birth.

Sichel's (fils)[16] cases (Cases 40 and 41) and Froebelius's[18] (Case 90) appear to illustrate the same point.

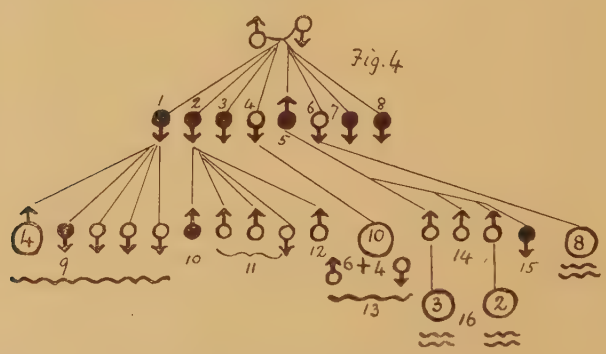

CASE 17 (Fig. 4).—Nine cases of senile cataract in 2 generations. Incidence earlier in second generation (P. and T., 22,231).

Generation I—

1, 2, 3, 5, 7. Cataract began in these at about æt. 65; four

of them died at ages from 69 to 81, only one (No. 7) still living, æt. 82 (1902). Cataract very slow in all, and none were operated. (No. 3 = P. 7,151.)

8. Cataract began about 60; operated with success, æt. 63; died, æt. 67, many years ago.

Generation II—

9. The eldest of the 4 daughters of No. 1; cataract began æt. 50 to 60; still living, æt. 70, in 1902, and cataract still not mature.

10. First-born of No. 2; cataract began æt. 45; both operated, æt. 51 and 54, successful; æt. 56 in 1902. (22,231.)

11. All living, æt. 54 to 49, in 1902, and no cataract.

12. Ob., æt. 26, accident.

13. Ten children of No. 4, 6 male, 4 female, none cataract.

14. Unmarried. No cataract.

15. Unmarried. Slight changes in lens, æt. 39, in 1898. In 1904 = æt. 45, opacity not increased. (45,168.)

16. These are still children (1902).

I have seen Nos. 3, 10, 14, and 15.

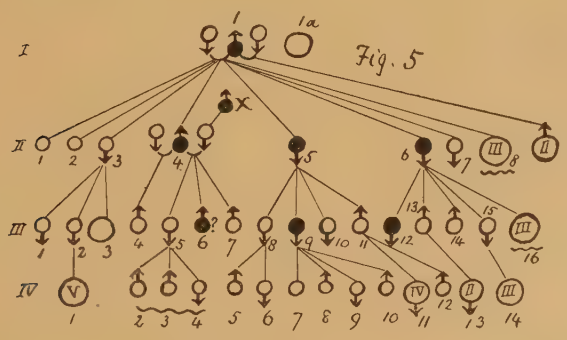

Case 18 (Fig. 5).—The Vesey family. Six (probably 7) cases of early senile cataract in 3 generations. (T.I.P. 1885 and 1897 also notes from Mr. Jessop.)

Generation I—

1. A working jeweller had to give up work about æt. 50, or earlier, from failure of sight, which was always spoken of by his children as cataract. Was not operated. Died between 50 and

60 years of age. He was one of several siblings (1*a*), but nothing is known of the others. He married twice; his wives not cousins either to him or to each other. By 1st wife, 10 children, of whom Nos. 4, 5, and 6 had cataract. By 2nd wife, 2 sons; both died young.

Generation II (by 1st wife)—

1 and 2. Died in infancy.

3. Daughter. Good eyes.

4. Fourth born (son). Both eyes operated for cataract, æt. about 45, and did well. Died æt. about 55. Married twice; the wives not cousins to him or each other. By 1st wife 1 son (III, 4). By 2nd wife 1 daughter, then 2 sons (III, 5, 6, 7); one of the four probably has cataract. The first-born by second wife (III, 5) had 3 children (IV, 2, 3, 4) who see well hitherto. The 2nd born (son, III, 6), now (1905) middle aged, has progressively failing sight, which his cataractous relations (II, 5, and III, 9) tell me they have no doubt is due to cataract; he refuses to be examined. X., the father of the 2nd wife of II, No. 4, is known to have had cataract, and died an old man without operation; therefore III, No. 6, inherits from both sides.

5. Mrs. Vesey (5th born). R. operated for cataract by myself, æt. 50 (1885); symptoms began about æt. 45. L. operated, æt. 57. Both did well. Now æt. 70 and sees well (1905). Has 4 children, of whom the 2nd has cataract (III, 9, below).

6. Emily (6th born). Both eyes operated for cataract, æt. about 40; cataract began about æt. 38. Has 7 children, of whom first-born (daughter) has cataract (= III, 12).

Generation III—

6. Probably has cataract (see above).

9. Mrs. Carter. Second born and 2nd daughter of II, 5. V. failed about æt. 38, 15 years after marriage, and 7 years after birth of youngest (4th) child. R. operated for cataract (Mr. Lawford), æt. 41 (1904), did well. L. incomplete cataract.

12. Mrs. Airs. First-born of II, 6 (Mr. Jessop's patient). R. began to fail, æt. 32, and Mr. Jessop extracted cataract, æt. 33 (1894). L. followed, beginning chiefly at posterior

cortex, and was extracted by Mr. Jessop, æt. 36 (1897). Both did well. Married 20 years, no children. Now æt. 43 (1905).

None of Generation IV, who are still all children, have as yet shown signs of cataract.

CASE 20.—Mr. Lawford and Mr. Fisher have given me the following case of 4 generations :—(T.I.P. 1894. No. 42.)

Annie S., first-born of 9. Sight began to fail, æt. 23. L. cataract removed, æt. 26 ; R. cataract removed (by Mr. Lawford), æt. 30 (1894).

Her mother, mother's mother, and mother's mother's mother all suffered from cataract comparatively early, and each was, like the patient, the eldest *daughter* of the respective childship. "In each generation the cataract appeared at an earlier age than in the one preceding it," but no particulars of the ages are given except for the patient (= 4th case).

It is, however, not uncommon to find that the cataract has come on at about the same age in all the affected members of a family. Bowman observed this, and it has been mentioned by others. In many such instances another feature, alluded to by Fuchs and others, has been the comparatively early age at which the malady has appeared in all the sufferers. Such a frequency of præsenile cases in family cataract does not, however, of itself prove that the hereditary tendency is more liable to manifest itself at an early age than in advanced life, for the greater the longevity of each generation the greater is the difficulty, other things being equal, of obtaining records of past generations.

The following cases illustrate the above points :—

CASE 18*a*.—Mr. —— (Fig. 5*a*, VI, No. 1), æt. 55, Mr. Lawford's patient at St. Thomas's Hospital ; cataract coming about a year and a-half ; extraction of R. with good result, April, 1905. Five children (2 sons and then 3 daughters) ; none have shown signs of cataract. He knows about his direct male ancestry for 5 generations back, but not the female and collateral members ; the pedigree is as follows :—

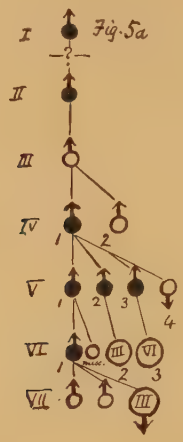

I. Male, had some disease of eyes called cataract about the year 1730.

My informant was not quite certain whether the next generation was son or grandson of I; if there was an intermediate there is no history of his having had cataract.

II. Colonel —— fought at the Battle of Culloden in 1745, and having afterwards to leave the country, lived for the rest of his life in France, where he worked as a bricklayer near Paris. He became blind from cataract, and was operated upon in Paris, probably about 1780, when aged 60 to 65. His eldest son (III) is not known to have had cataract, but his history is really lost. III had two sons :—

IV. 1. Eldest son of III. Cataract. Was a florist near London. Was operated on with good result when about 60, and lived to be 93.

2. George, believed not to have had cataract.

V. Children of IV, 1—

1. Eldest son, George, operated for cataract at Moorfields by Mr. Tweedy at the age of about 53 and lived to be 84.

2. John, also operated by Mr. Tweedy at about the same age and lived to be 76, dying in January, 1905.

3. Alec, 3rd brother, operated by Mr. Tweedy when rather more than 50, and died æt. 70 in 1904.

All the above did well after the extraction.

4. Daughter, emigrated when young and not heard of since.

VI. 1. The patient, only living child of V, 1; there was 1 miscarriage.

2. Three children (2 male, 1 female) of V, 2; none have cataract.

3. Six or 7 children of V, 3; all believed to have good eyes.

VII. Five children of VI, 1 (see above).

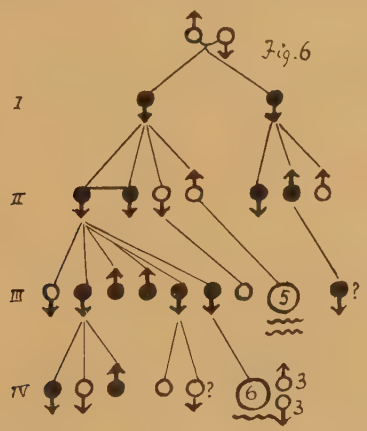

CASE 19 (Fig. 6) (14, 54 and T. I. P., 1888, Heath).—Mixed senile and præsenile cataract in 4 generations. No clear evidence of earlier incidence in the younger generations.

The ages of the two cataractous persons of generation I are not known.

The ages of 3 out of the 4 cataractous persons of generation II were "old age," "about 80" and 50 respectively; age of the 4th not known. Note that both the twins were affected.

The ages of the 5 cataractous ones of generation III were—

about 50	when	operated on in	2
30	,,	,,	1
65	,,	,,	1
50 when diagnosed ...			1
			5

In generation IV there were 2 cases—

Cataract beginning at 40 in 1
„ operated „ 33 „ 1
—
2

There were 13, perhaps 14, cases in all, and of these 7 are known to have been operated. No fresh cases have occurred in Generation IV since 1888.

No consanguinity known; but all the patients lived within 10 miles of each other in an agricultural county (Lincolnshire), where the family had been settled for a long time.

Case 21 (51,166).—Cataract began in mother at about 35 to 40, and in daughter, æt. 30 to 35. In mother V. was still pretty good, æt. about 50. The daughter's was the cortical dotted form with some blue opacities; of the mother's, no particulars are given.

Case 22 (35, 26).—Mother operated for cataract, æt. 89.

Son, early changes, æt. 70.

Case 23 (29,132).—Cataract very slow in mother, now æt. 92, and son, now æt. 70.

Began at about 60 in son, and may have done so in mother.

Case 24 (17,147).—Mother and daughter; cataract very slow in both.

Daughter not much worse æt. 72 than 50.

In Hirschberg's[11] case (Case 34) of 3 generations the cataract was observed at about 28 in all but one of the subjects, and operated at 30 to 35.

In Klamroth's[12] (Case 35) it came between 21 and 23 in father and his twin sons, and was operated at 29.

Other cases, illustrating onset at about the same age in each generation and described further on, are those published by Schanz (Case 26), Streatfeild (Case 28), Tatham Thompson (Case 36), Appenzeller (Case 38), Arago (Case 39), and my own Cases 32 and 33.

There appear to be but few cases in which cataract

comes on at a later age in the succeeding generations. The following is one:—

CASE 25 (47, 89).—Mother operated for cataract, æt. 50. Son, cortical opacities, æt. 54.

It seems from the foregoing facts that *there is some tendency for hereditary cataract, both senile and præsenile, to appear earlier, or, at any rate, to ripen earlier, in the younger generations.* But evidently great differences in this respect occur between different families,* and even between different members of the same childship, and the point is one upon which fuller and more accurate information is much to be desired. Certain cases (*e.g.*, Case 34) raise the question whether "Anticipation" if carried far enough may not reach the child *in utero,* and thus lead to some form of congenital cataract.

6. When *senile cataract* affects several siblings, does it come on at or about the same age in all?

In Case 19 (Heath family) the cataract is said to have come at about 50 in 4 of those affected in the 3rd generation and at 30 in 1, that one being the 5th born of 6 and dying of phthisis at 38.

In Case 17 (P. T. family) no marked difference of age at onset was known: the cataract came on at about 65 in the 5 elder of the 6 cases in Generation I, but began decidedly earlier, or ripened decidedly earlier, in the 6th patient, who was the 8th born of 8 (began 60, operated 63).

Cases of Præsenile and Juvenile Acquired Familial Cataract illustrating some of the preceding Questions.

Cases 19 and 20, already given, belong to this group.

CASE 26 (Fig. 7).—Schanz [20] published the following case of cataract coming on in the twenties in 3 brothers, whose father

* Galezowski (21) has a very similar remark on this subject in Rec. d'Ophthalmologie, 1882, p. 719, etc.

probably had cataract developing when he died, æt. 40. It is just possible that in the youngest subject (No. 7) the cataracts were self-made, in order to escape military service, but this does not apply to No. 3.

1. Father, died at 40 of lung disease. Sight defective during the last years of life, and was told an operation would be needed later. Could see to work till the last.

2. Girl (1st born), died æt. 7, in consequence of a fall.

3. (2nd born) Julius P. Passed army tests; afterwards sight became dim, æt. 26, in R., and then L. Both matured rather quickly. Operated before æt. 30. No fits.

4. (3rd born), died, æt. 2; said to have had disease in neck, and swellings on arms. Sex not given.

5. Son (4th born), died, æt. 13; cause not stated.

6. Josef (5th born). History of corneal ulcers and scrofulous glands. Sight pretty good till æt. 18, when he rapidly became blind. Not seen by author, but cataract inferred (æt. 26 in 1897).

7. Son (6th born), æt. 23 (1897), a tailor. Sight quite good till about æt. 22. Then rapidly forming cataract in R.; becoming complete in *two months*. L. rapid also, and operated within a few weeks of operation on R. Note that this man had been put back from beginning his military service for a year for general debility and that the cataracts formed rapidly (2 months) during that year.

No sugar or albumen in any of the patients.

CASE 27 (Fig. 8).—Berry [25] published in 1888 what is probably the most remarkable example of hereditary cataract hitherto recorded, 55 individuals, spread over 5 generations, furnishing no less than 20 cases. In all the cases the cataract developed in early life, usually in childhood (æt. 7 and 9 in 2 cases), occasionally in adolescence (æt. 18 in 1 case). It became complete. The pedigree (Fig. 8), is from Berry's paper, but my own signs

have been used. In no case did the eldest girl in an affected childship escape.

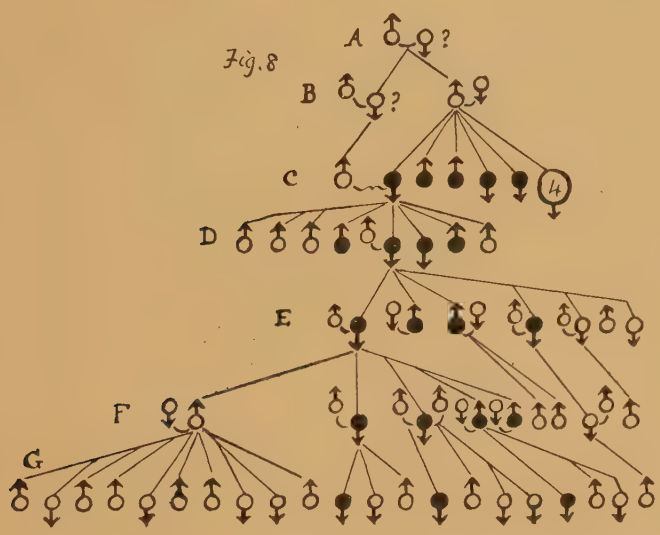

CASE 28 (Fig. 9).—In 1858, Streatfeild[7] published the following case:—

1. Mother. Cataract discovered, æt. 1½. Operated incompletely. Was æt. 33 when seen.

2. Cataract came on, æt. 6. Operated; æt. 16 when seen.

3. Died, æt. 5; no known defect of sight.

4. Cataract operated; æt. 11 when seen.

5. Cataract not operated; æt. 9 when seen; grey opalescent cataracts.

7. Cataract not operated; æt. 5 when seen; diffuse cataract not so advanced as No. 5.

8. Cataract began, æt. $1\frac{1}{2}$; not operated; æt. 3 when seen; opacity chiefly at lower part of lens.

9. No cataract; examined when æt. 8 months.

The cataract in all cases said to have come on so rapidly as to cause practical blindness in 4 to 6 weeks, sight having been previously good. In the eldest (No. 2) sight was good till æt. 6; in No. 8 only till æt. $1\frac{1}{2}$. Mother and all affected children grey irides and very light hair, almost colourless in the younger ones. Colour of eyes and hair probably same in the unaffected children as in those with cataract. Mother, eldest of four, has two sisters and a brother with brown eyes and good sight. No nystagmus in any. All good health, and well nourished.

CASE 29 (Fig. 10).—Palmer (15,147 and M., I.P. 1889):—

1. Father. Posterior cortical cataracts diagnosed, æt. 31 (1887). Both complete, æt. 33, and operated with success (1889). 1904, æt. 38, V. keeps good.

2. First-born of No. 1. Sight began to fail at æt. 24 (1904), when Mr. Fisher found posterior cortical cataract.

3. Æt. 18 (1904).

4. Æt. 15 (1904).

5. Æt. 13 (1904). Wears weak + glasses for hypermetropia.

CASE 30 (Fig. 11).—Culverwell (T.I.P., 1885, and O.P. letter):—

1. Aunt (? maternal or paternal). Posterior cortical cataract, both, æt. 36, with R. 6/18 not improved, some old choroiditis;

L. – 3 D., 6/9, some old choroiditis, and less opacity of lens than R. R. failing since, æt. 20.

2. Grace Culverwell. V. thought to have always been bad. Æt. about 9 (1885), posterior cortical cataracts. L. needled, curetted, and suppurated. 12 months later (1886) R. preliminary iridectomy followed by extraction in two months; purulent iritis and shrinking of globe. No fits. Teeth normal. A long illness with vomiting whilst teething. Measles and whooping cough, æt. 2 years.

Mother pulled down by nursing husband with bad typhoid towards end of pregnancy.

3. Ellen. Cataracts chiefly posterior cortical, found æt. 8 (1888), getting worse; had seen quite well, æt. 4. No operation.

4. Æt. 11 in 1885; good sight.

5. „ 7 „ „

CASE 31 (Fig. 12).—Bt. (36,178):—

1. Mrs. Bt. Dotted peri-nuclear and cortical cataract diagnosed, æt. 32. No definite history, but always slightly myopic. Only seen once (1889).

2. Sister of Mrs. Bt. (= Mrs. Bl.). Peripheral striæ, chiefly below, æt. 30 (1895). Only seen once.

3. Daughter of No. 1. Similar dotted cataract diagnosed, æt. 14 (1898).

CASE 32 (M., 53,100).—1. Grandfather; cataract in both, æt. 36, operated several times with poor result. Lived to be 84.

2. Mother; free.

3. Daughter (Mrs. M.); cataract diagnosed in R., æt. about 35. When seen, æt. 38 (1900), half complete. L. had marginal opacities æt. 38. No cyclitic signs in either eye.

CASE 33 (Wood, T.I.P., 1881, No. 79) :—

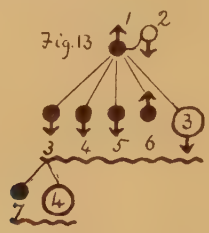

1. Operated for cataract when a young man, and wore glasses after. Died, "brain-fever," æt. 43.

2. Wife of No. 1; good sight. Died, bronchitis, æt. 79.

3. Lydia Wood.—L. cataract began about æt. 33; operated in the country æt. 35; did badly and went into secondary glaucoma. R. began about æt. 35; extraction of softish but much shrunken lens (St. Thomas's Hospital) æt. 40; scoop extraction and loss of rather thin vitreous; 5 weeks after operation V. 6/12. Health and previous history good.

4 and 5. Two sisters died in early childhood; both said to have cataract.

6. Brother now (1881) nearly blind from cataract; age not stated.

Then came 3 sisters, of whom 2 living (1881), near-sighted but see small things well; the 3rd died, æt. 37, after a long illness.

7. Child (? sex) of No. 3. Blind in one eye; no history of inflammation or ophthalmia; doctor said "cataract." Died æt. 18 months of whooping cough.

Then 4 other children of No. 3, healthy and see well.

CASE 34 (Fig. 14) (from Hirschberg [11]) is as follows :—

The parents of Generation I had good sight.

1. Samuel E. was operated for complete cataract with success when æt. 30.

2. Had one eye operated for cataract by v. Graefe æt. 28. Seen by Hirschberg æt. 41 (1874); operated eye good, other complete cataract.

3. Good eyes æt. 38 (1874). Has 5 children, all free from cataract.

4. Sight began to fail æt. 28; had previously seen well enough to go through his military service. Now (1874) æt. 36 double cataract ready for operation.

5. Cataract formed at about æt. 28. Seen æt. 29 (1874) with cataract complete in L., and nearly so in R. L. extracted with perfect result.

6. Daughter of 5, æt. 12 months (1874); double "congenital lamellar" cataract, for which iridectomy performed. A fine healthy child.

The history of this family was that sight was quite good in Generations I and II till about the age of 28. No sugar in urine. The men were all big and strong.

CASE 35 (Fig. 15).—In the same year Klamroth [12] published the following example:—

1. Father, cataract came on at about the same age as in his 2 sons.

2 and 3. Twin sons of 1.

In No. 2, a labourer, cataract began at about æt. 21 and got gradually worse. At 29 (1874) L. operated with good result.

In No. 3 the cataract began at about æt. 23 and at 29 was complete in L. and incomplete in R. Operation with good result.

The twins attributed their own disease to the heat from brick-

kiln at which they worked; but author thinks the brick fire was not enough to cause it. No mention of father's occupation.

CASE 36 (Fig. 16).—The following example of cataract coming on in childhood in 4 generations was published by Tatham Thompson[37] in 1890. The opaque lens in some of these cases was remarkably hard, in fact, allied in texture to cataract of older people.

The pedigree is copied, with slight modifications, to suit my own "key," from Thompson's paper:—

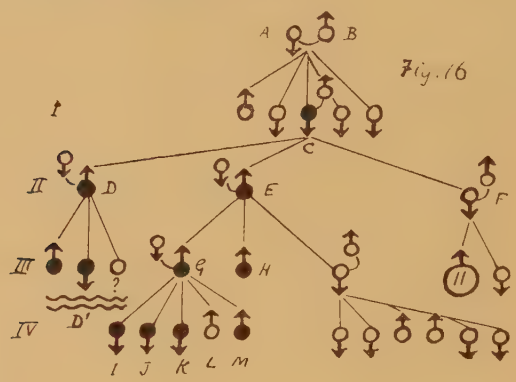

A and B. Had no cataract.

C. Cataract came in childhood; operated, æt. 12.

D. Became blind with cataract, æt. 5, and was operated.

E. Became blind of cataract and operated, æt. 5.

D'. Children of D, number and sex not known, but some of them known to have had cataract.

G and H. Both developed cataract at from 3 to 5 years of age, operated, and did well. H died, æt. 11.

I, J, and K. Developed cataract rapidly at æt. 2 to 3.

L. Examined and found free from opacity at æt. 3.

M. Commencing cataract, found when examined, æt. 7 months.

CASE 37.—Dor[38] gives the case of a father who had been operated for double cataract at the age of 25. The operations failed, and he became quite blind, but he afterwards married and had 8 children, of whom the 6 eldest had good sight; the 7th

(male) was found by Dor when æt. 7 to have semi-soft degenerated cataracts and nystagmus, and was operated with good result. The 8th child died of infantile diarrhœa. Dor's record of the nature of the father's cataract was, necessarily, incomplete.

CASE 38.—Appenzeller's[24] Case 1 is that of 2 brothers and a sister, in all of whom cataract developed rapidly between 20 and 30 years of age. They were part of a childship of 7, but the places of the cataractous ones and the sexes of remaining 4 are not given.

The parents had good sight, and were not cousins.

CASE 39 (Fig. 17).—In 1884 Arago[23] recorded the following case, the pedigree of which I reproduce in terms of my own "key":—

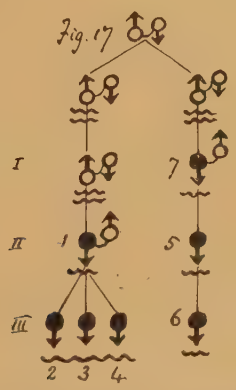

1*st Branch.*—1. Nuclear cataracts complete, æt. 30; operation success.

2. Medium hard cataracts beginning, æt. 28; operation, æt. 38; success.

3. Soft cataract began, æt. 27; operation, æt. 33; success.

4. Cataracts from childhood, æt. 21; R. shrunken, L. soft; both operated; success.

2*nd Branch.*—5. Cataracts began, æt. 30; very slow; æt. 57, L. medium hard, complete; operation, success.

6. Cataracts began, æt. 20; L. ready, æt. 24; operation, fair success (conditions difficult).

7. Cataract not proved, but was blind, and was operated by a travelling oculist. Died blind.

CASE 40 (Fig. 18).—Sichel (fils)[16] records the following, in which senile cataract "anticipated" through 3 generations, and became finally an affection of early life. The direct continuity, however, was broken :—

1. Operated for double hard cataract in 1845 by Sichel (père). Age at date of operation not stated.

2. Son of 1 ; good eyes.

3. Daughter of 1 ; had double juvenile cataract, which was complete at the age of 18, and operated in 1862 by Sichel (père).

4, 5, and 6. Three cataractous children of No. 2 (who had no cataract). Each was operated in 2nd year of life by Sichel (fils), in 1869, 1872, and 1877 respectively. He calls it "congenital cataract" without further description.

CASE 41.—In another very similar case, Sichel (père) operated for double hard cataract in 1854 upon a man, æt. 62, and in 1865 upon his son, æt. 46, for double semi-soft cataract ; and, finally, Sichel (fils) operated on a son and daughter of the last man (grandchildren of the first patient) at the ages of 13 and 9 for "congenital" cataract that had become complete.

CASE 42.—Females only : 3 generations. Sichel (fils) states that his father operated on a woman and, later, upon two of her daughters, whilst he himself finally operated on a daughter of one of the last patients (maternal granddaughter of the first patient). The ages of these patients are not given.

The following new cases of præsenile and juvenile cataract are given by Daust[45] :—

CASE 43 (Daust's Case 9).—Father, cataract when young ;

son, punctate cataract diagnosed at 25, but had probably existed from a much earlier age.

CASE 44 (Daust's Case 16).—Shrunken cataract in one eye only of woman aged 34; sight of this eye had never been so good as other; no injury known. Cataract since early youth in 2 sisters of mother, mother herself having good eyes.

Whilst of previously-published cases not hitherto referred to in the present paper, Daust gives the following in abstract:—

CASE 45 (Bock [48], Zehender's Klin. Monatsbl., 1886, p. 227). —Mother, aged 43, a peculiar form of congenital cataract; no evidence of constitutional disease. Daughter, aged 8, double nuclear cataract; and her other children (number not stated) said to have been born with cataract. Mother states she was born with the disease, and that vision has got worse. She has nystagmus, small cornea, deep a.cs., and tremulous irides. Teeth good in her and her children, and no signs of rickets in any.

CASE 46 (Fig. 19).—Fukala [46] (Internat. klin. Rundschau. Wien, IV, p. 1155):—

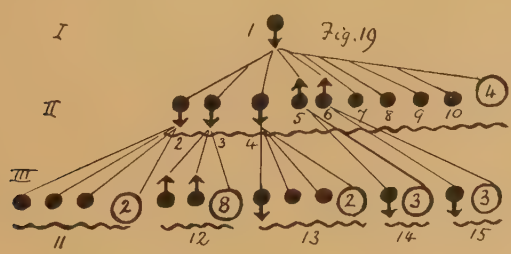

1. Double cataract. She had 13 children.

2 to 10. Nine of the 13 who had cataract, and 4 of them transmitted it.

11. Five children of No. 2, of whom 4 had cataract.

12. Ten children of No. 3, of whom 2 (sons) were affected.

13. Five children of No. 4, 3 of whom were affected, 1 of them (girl) being the patient.

14. Four children of No. 5, 1 of whom (girl) suffered.

15. Four children of No. 6, 1 of whom (also a girl) was affected.

In the whole family the cataract appeared at an early age.

CASE 47 (Fig. 20) (Ziem [47]) :—

1. Had cataract.
2. Had cataract.
3. Double stellate cataract.
4. Said to have had partial diffuse cataract.

5 and 6. Two sons of 3, aged 19 and 14, both stellate cataract; the one aged 14 was the patient.

7. Man, aged 34, son of 4 and cousin of 5 and 6, also had the same sort of cataract.

CASE 48, Rampoldi [49] (Fig. 21) (Cat. nucleo-corticale in quatre individui della istessa famiglia) :—

1. Operated for cataract. Had 7 children, of whom 4 died with good eyes before 30 years of age, and 3 had cataract, viz.: Nos. 2, 3 and 4.

2. Nucleo-cortical cataract at æt. 38.

3 and 4. Sister and brother of 2, have been operated for cataract.

Case 97, p. 240 (Gjersing's case), should have been placed in this group.

B. CONGENITAL CATARACTS.

This group, as a whole, contains 183 patients, of whom 90 were males and 93 females; besides about 55 others whose sex is not given.

I. We have first a small group in which the cataract is recognised almost at birth or within a few weeks, and is either complete from the beginning or very soon becomes so, and often becomes partially absorbed if not operated upon early, this spontaneous shrinkage leaving a firm central disc or mass completely filling the undilated pupil.

Sporadic cases of this kind are not very rare, but I have found only 9 familial examples, and in 7 of these the cataract was confined to one generation. Two of the cases are my own, 7 are from literature.

The 10 sets of siblings contain 27 cases—male, 13; female 10 (sex unrecorded in 4).

The births of the affected children were successive in 3 instances; in 2 of these certainly, and the 3rd probably they were the 1st and 2nd born. The parents in 4 cases were first cousins.

In 4 others the affected ones were separated by 1 or more children with good eyes; in no one of these 4 was the first-born child known to be cataractous.

In Westhoff's [32] very fully recorded case (Case 51 below), 3 boys, born with complete cataract, were the only survivors of 6 children, the other 3 dying at birth or in early infancy.

In several others there are records of infantile deaths.

The cases certainly produce the impression that we are dealing with some general morbid condition often powerfully affecting the whole offspring and sometimes occurring in both parents. There is no mention of syphilis in any. The cases are as follows:—

Hirschberg [27] has recorded congenital cataract in two pairs of infants of different families. (Cases 49 and 50.)

CASE 49.—Family L. 1. Lina L., æt. 4 months (1874), complete double congenital cataracts. No complications. Both lenses needled, with an interval; child died of "dysentery" before absorption was complete.

2. The next child (sex not stated) was brought with double complete milky cataract a few days after birth; ps. dilated unusually well to atropine. At æt. 9 weeks, when brought for operation, spontaneous absorption had begun, p. having become almost clear on temporal side in L. and nasal side in R. Both needled (November, 1876, and March, 1877) with good result. Child died in early life.

Parents sound.

CASE 50.—Family R. 1. First-born, male (Curt R.); seen, æt. 1½, with both eyes shrunken after unsuccessful operations performed at æt. 6 months at another hospital. Died a few weeks later of diphtheria. History shows that child was born with small eyes and opacity of lenses.

2. Female (Erna) also born with opacity of lenses, and when seen, æt. 6 months, eyes were small (corneal diameter 8 mm.), and ps. not dilatable by atropine. Iridectomy performed, and periphery of lens then found to be clear, but exact character of the central opacity not made out; visual power good.

Parents first cousins, but had good eyes.

CASE 51 (Fig. 22).—By Westhoff[32]:—

1. Father; perfect eyes; good health; carpenter. His father died of apoplexy, with perfect sight. His mother living, æt. 60; perfect sight. No note as to syphilis.

2. Mother; healthy, slight hypermetropia. Her father died, æt. 66, of cancer of stomach; had good sight. Her mother living, æt. 76, with good sight.

3. First child, stillborn.

4. Pupils noticed by parents to look grey soon after birth;

and child, whilst following the movements of a flame, did not try to grasp things presented to it. Seen by W. with complete cataracts, æt. 7 months, but not operated till æt. 1½ year, when needled with success, and at æt. 6 V. with glasses very satisfactory, and fundi n. No fits. General condition very good.

5. Seen by W. soon after birth; no trace of cataract. Died of meningitis, æt. 16 months.

6. Seen by W., æt. a few months with double complete cataract and nystagmus. Needled; good result. No convulsions.

7. Died in convulsions, æt. 4 days. Parents and nurse reported pupils quite black and clear.

8. Seen by W. with complete cataract in one eye, the other being healthy; exact age not stated. Had some fits, otherwise well. No operation.

The 6 children were born between 1887 and 1895, the longest interval, 2½ years, being between Nos. 6 and 7.

CASE 52 (Fig. 23).—Gerok[34] has the following instructive examples of "congenital" cataract of unnamed variety:—

1 and 2. Husband and wife, first cousins; one of them had cataract, but it is not stated whether husband or wife.

They had 3 cataractous children.

A case of cataract (3) had occurred in the generation of siblings, from which 1 and 2 derived their cousinship, but whether 3 was a parent of either 1 or 2 is not stated.

CASE 53 (Fig. 24).—Appenzeller's[24] Case 2 is as follows:—

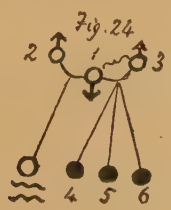

A woman (1) married a man not related by blood (2) and had children, all of whom had good sight. He died, and she then married her first cousin, who also had good eyes (3), and by him had 3 children (4, 5, 6), all of whom were born with double congenital cataract.

No. 4 (sex not stated) was æt. 4 at the date of publication; no particulars of the cataract.

5. Girl, seen by author at æt. 3, had nuclear cataracts with projecting spicules and clear cortex; it is described as peculiar, and was presumably not lamellar. Sex sign omitted in figure.

6. (Sex not stated.) Born 2 years after No. 5; had double cataract, and died at 5 weeks.

No known malformations in the ancestors of either 1 or 3.

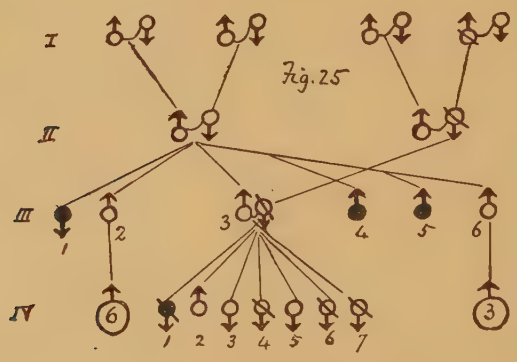

Case 54 (Fig. 25) (Appenzeller's Case 5).—A girl (IV, No. 1 on pedigree), the first born of 7, was blind at birth, and when examined at 10 years old had dense white cataracts; she also had a malformation of the fingers of both hands. Of the remaining 6 siblings, No. 2 was a boy, and the other 5 girls; none of these had cataract, but Nos. 4, 6, and 7 (girls) had the same malformation of fingers. This malformation (indicated by an oblique line in the diagram) came from the mother's side (Generations I and II). The cataract came through, but not directly from, the father (III, No. 3), 2 of his brothers and 1 sister (III, Nos. 1, 4, and 5) having been born blind (no particulars); and it is to be remarked that the blind sister

(III, No. 1) was the first born of 6. No consanguinity on either side in any generation.

CASE 55 (Appenzeller's Case 7).—A boy of 3 years had cataracts of an indeterminate form and somewhat shrunken; said to have been born with them; no microphthalmos. His father had bad sight from early life, and had been operated successfully for cataract. No consanguinity, and no history of cataract in father, brothers, and sisters, nor in their children.

I have found notes of only 2 cases of my own.

CASE 56 (Fig. 26).—Dearsley (G. B., 1, 168):—

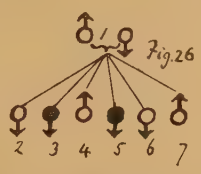

1. Parents, first cousins; good sight. No known history of cataract in previous generations.

2. Æt. 25. One eye blind from corneal ulcer.

3. Edith, æt. 23. Cataracts were seen within 1 day of birth. Operated 5 times between æt. 11 months and 6 years. R. did badly, and shows general opacity of cornea with good p.l. L. did well; p. clear; good fundus reflex; nystagmus; never fits; teeth good.

4. Died, diarrhœa, æt. 13 months.

5. Ivy, æt. 18. Dense central cataract. ? Small lamellar, or shrunken lens leaving clear border. Iridectomies, æt. 5; never fits; teeth quite good.

6. Æt. 15; good eyes.

7. Died, æt. 5 months; had fits.

Intelligence good in parents and all the living children.

CASE 57 (Fig. 27).—Kingshott (T.I.P., 1879, p. 179):—

1. Father good sight.

2. Mother good sight; had repeated floodings whilst pregnant with No. 3, but not with No. 4. Died, bronchitis, when No. 5 was æt. about 5 months. Had 11 children.

3. James, 5th child. Cataracts recognised the day after birth. When æt. 3 to 4 years, operated several times. Seen by me, æt. 8 (1879), ps. round and active and a perfectly clear hole in L.; capsule in R. Sees 18 J., with +12 D. Æt. 17 (1888), L., reads tolerably small print with 19 D. No fits. Intelligence good, but head narrow, and boy generally undergrown.

4. Ellen, 8th child. Seen æt. 3 years (1879), with dense yellowish white central cataracts and nystagmus. The opacity consisted of a much shrunken, flattened lens, with nearly clear zone of capsule between it and ciliary processes, through which plenty of light passed. Opacity friable to needle and easily broken up. One eye lost by suppuration. No fits.

5. Three others who died at 6 years, 5 months and birth respectively; their places in the family not stated, except that the one who died at 5 months was the last born of the eleven.

All except 3, 4, 5 on pedigree, healthy.

CASE 57*a* was published by Mr. Donald Gunn[52] in 1898, and since then the family has been under the care successively of Mr. Lister and Mr. Parsons at the Hospital for Sick Children. Three generations affected: I, female, cataract became apparent at about 18 years of age; married and bore 7 children (II), of whom Nos. 3, 4, 5, and 6, all males, were "born with cataract." Of the remaining 3 who escaped, 1 was a girl, the sex of the other 2 not stated. No. 3 of Generation II, male with cataract, was operated at age of 16 at Moorfields. He married, and his wife has 4 children (Generation III); there has also been 1 miscarriage; the first-born (girl) has H.As., but otherwise good eyes; 2nd (girl, Maud Bragg) had (in 1897), when 2 years old, shrunken cataracts and nystagmus; she is now (1905) about 10½ years old, and, after repeated needle operations, had V. 6/36 with +8 D.; 3rd (boy), good eyes; 4th (boy, Stanley Bragg), was seen (in 1901) at æt. 1 year, with double cataract (no description), and has undergone several operations with fair success, and is still (1905) under notice.

Other Varieties of Familial Congenital Cataract.

II. Next to lamellar cataract (see below), one of the best marked varieties is the peculiar and apparently rare form called *Axial or Spindle cataract* by the Germans, or, to use Mr. Marcus Gunn's [39] term, *Coralliform cataract*, in which the opacity appears from the history to have been present quite early in life, if not actually at birth, and remains, like the lamellar form, almost stationary, seldom becoming complete.

By far the best example of this sort that I have seen is that of the Betts family (Case 58), in which no less than 30 persons in 4 generations are known to have been affected.

In another, the Ch. family, only 2 siblings were known to be affected.*

Probably some of the cases described by Knies [13] (Case 60) as spindle cataract, and previously under a different title by E. Müller [35], were of this kind; Knies, however, in some of his cases, describes the characters of axial and lamellar cataract associated in various degrees in the same lens. Two of the children in my Case 58 had lamellar cataract, their fathers having coralliform opacity. Moreover, in cases of familial lamellar cataract, atypical forms are occasionally seen (*e.g.*, Galezowski's [21] Cases), some of E. Müller's, and Cases 34, 63, 74, 76, 77, and 79, in which the cataract was not of the same kind in the child as in the parent. Although, therefore, it is necessary for descriptive purposes to keep the axial or coralliform apart from the lamellar cataract, it may, perhaps, be found eventually that both arise from the same, or similar, causes operating at different stages, or over longer and shorter periods of fœtal life.

In this little group, transmission has been continuous in every instance.

The disease attacked successively born siblings often,

* At the June meeting of the Ophthalmological Society Mr. Fisher showed a new case of this form of cataract, referred to below as Case 58*a*; and I have added another, probably of the same nature, seen at St. Thomas's Hospital in 1894 (Case 58*b*).

but by no means always. The first-born, whether boy or girl, was usually affected.

The sex prevalence is quite different from anything we have met before: of 46 cases, male, 25; female, 21.

Descent in 15 *parentages*, through mother 8 times, through the father 7 times.

Descent to same sex or opposite varied.

CASE 58 (Fig. 28).—Betts family. Fig. 28 shows a pedigree of more than 90 persons (probably at least 100), of whom 30 are known to have or have had cataract; and 19 of these have either

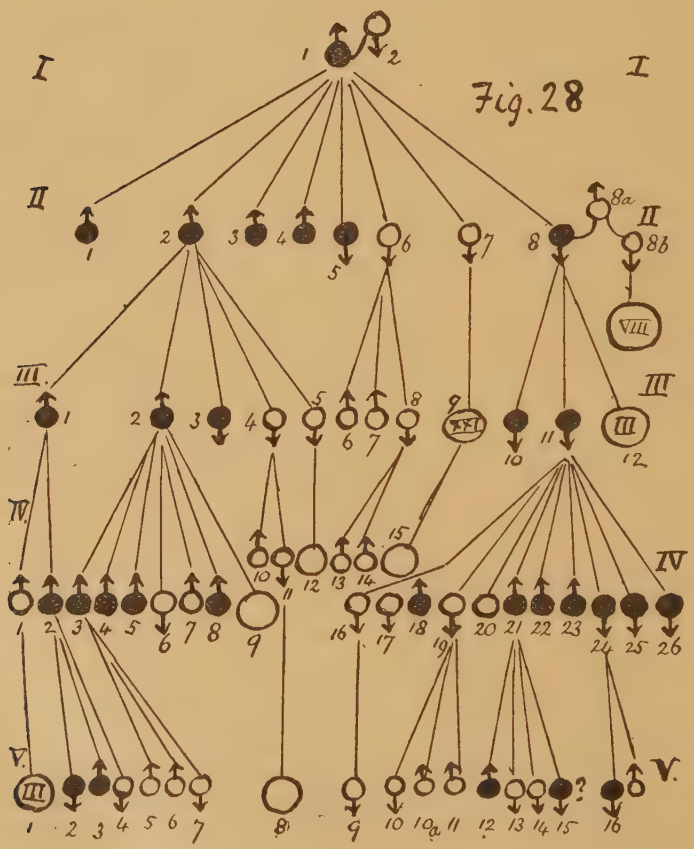

been seen by myself, Mr. Marcus Gunn, or Mr. Walter Sinclair of Ipswich; or are known to have been operated for cataract either at Moorfields or by the late Mr. Bader at Guy's Hospital.

Judging by the history, the cataract must have been present at birth in all cases; it is usually almost stationary, but in two cases some shrinking of the lenses occurred after middle age. With two exceptions, it has presented the same features in every case that has been seen, features very accurately depicted in Mr. Holmes Spicer's drawing of the case (Generation IV, No. 2 in pedigree) published by Mr. Marcus Gunn in vol. xv of the Ophthalmological Society's Transactions (1895), and for which Mr. Gunn has suggested the name "Coralliform." The opacities take the form of dense blunt-ended processes radiating obliquely forwards and outwards (*i.e.*, towards the equator), but not reaching the capsule. Each spoke or process ends peripherally in a sort of trumpet-shaped enlargement or "mouth," not unlike the "mouth" of a madrepore coral. By Knies they have been compared to the sails of a windmill. The intervening parts do not as a rule become quite opaque, even in old age (*cf.* Generation III, No. 11). In two of the cases of Generation V (viz., V2, and one not shown that should lie between 7 and 8)* Mr. Sinclair found ordinary lamellar cataracts, not the coralliform variety. Cholesterine is often present in coralliform cataract.

There has been nothing special in the health or development of this family and no reason to suspect any constitutional disease; no history of convulsions; no deafness. The first known cataractous ancestor was in a small business at the little agricultural town of Hadleigh, in Suffolk. The second generation, and many members, if not all, of the third, also lived or were born there, and some still reside either there or at Ipswich, a few miles off. A large contingent, however, are descended from a mother who left Hadleigh about 40 years ago and has lived near London ever since. There are, I am told, a great many persons named Betts at Hadleigh, some of whom do not recognise any

* Since Fig. 28 was constructed, Mr. Sinclair has discovered that No. 5 of Generation IV has married twice and had 5 children: 1 by the 1st wife, 4 by the 2nd. The one by 1st wife (a boy) had *lamellar* cataracts, and was operated by Mr. Sinclair 10 years ago. The 4 (3 male, 1 female) by 2nd wife have been examined, and all have good eyes. These 5 children should appear between Nos. 7 and 8 in Generation V.

kinship with the cataract clan. Several of the non-cataractous people of this name have married their cousins, but we have not succeeded in tracing any cousin-marriages within the stock known to be affected by cataract, though thorough enquiries have been made.

My acquaintance with this family began in 1883 with the history of Generations I and II, and the cases derived from Generation II, No. 8. For the discovery, quite recently, of those descended from Generation III, Nos. 1 and 2, and for other details, I have to thank my friends, Mr. Edward Howarth, of the Oxford Settlement, Stratford, and Mr. Walter W. Sinclair, Ophthalmic Surgeon to the Ipswich Hospital, who has examined several of them himself. Dr. H. Footman Everett, of Hadleigh, has also most kindly assisted in the search.

A general view of the pedigree shows that the transmission of the cataract was always continuous, *i.e.*, every cataractous child had a cataractous parent; and that of the cataractous ones a decided majority were males (20 males, 11 females), whilst among the 31 with good eyes whose sex is stated 14 were males, 17 females.* Also it is evident that the cataract had no relation to fecundity in the earlier generations. Generation IV, however, has produced comparatively few children (about 30), and of its 6 cases of cataract, 2 have already died; the prospect of transmission to a sixth generation seems therefore to be but small.

Generation I—

A man named Betts, a sack-maker by trade, had bad sight, which his granddaughters (III, 10 and 11) told me was always said by his children (Generation II) to be due to cataract. His wife is known to have had good sight.

Generation II—

1. Robert Betts, cataract, died unmarried.

2. William, cataract. Died about 1887. Five children, of whom the 3 eldest had cataract, the fourth and fifth (daughters) having good eyes.

* In this enumeration the 5 children of IV, 5 (1 boy with cataract, 3 boys and 1 girl with good eyes) not shown on the pedigree, are included.

3, 4 and 5. All had cataract; 3 and 4 married, but left no issue; 5 did not marry.

6. No cataract; had 3 children, all with good eyes.

7. No cataract; said to have had 21 children, all with good eyes.

8. Cataract, Susan B., second wife of Skinner (8*a*), who by his first wife, (8*b*), had 8 children, all with good eyes.

Susan (No. 8) born with bad sight, died at 50, not having had any operation; she had 5 children, of whom the 2 eldest (daughters) have cataract; the 3 youngest died in infancy, and the condition of their eyes is not known.

Generation III—

1. Charles, cataract, operated at Moorfields about 1875, and is still living. Has had 2 children (sons) of whom the younger had *coralliform* cataract (IV, 2); his case was published, with coloured plate, by Marcus Gunn in Oph. Soc. Trans., vol. xv, p. 119, 1895, when patient was 22 years old.

2. John, cataract, operated at Guy's Hospital. Has had 8 or 9 children (order not quite correctly shown on diagram); the first 2 or 3 died in infancy, and the condition of their eyes is not known; then 3 sons with cataract, and a fourth son, the last born (IV, 8), now dead, also had it. The eldest cataractous son (IV, 3) was operated at Moorfields in 1892–3; the other 2 living cataractous sons (IV, 4 and 5) have not been operated upon.

3. Mrs. Glanfield, cataract, operated at Moorfields in 1889 at the age of 51, moderately good result, still living (1905). The cataracts were densely white and appeared to be shrunken; a.cs. deep. Vision had never been good. Had only 1 child, born at seventh month and did not live.

10. Mrs. Warne, cataract, now (1905) aged about 71, and still sees to read with R. eye. R. eye was "needled" at Moorfields when she was 27 and has served her fairly well; when I saw her at about the age of 50 (1884) V. + 14 D = 6/60. L. eye never operated; in 1884 the cataract was complete and shrunken. Has had no children.

11. Mrs. Cross, cataract, R., has been operated; L. typically "coralliform" like IV, 2. Has been seen at intervals since 1884;

last seen January, 1905, æt. 64; L. lens much the same as 20 years ago, but there is now sufficient general haze to prevent illumination of fundus. R. operated repeatedly when aged about 38 without result; now secondary glaucoma. Has had 10 children and one miscarriage (IV, 16 to 26), of whom 7 have cataract.

Generation IV—

A. Children of III, 1—

1. William (of Hadleigh), good eyes; 3 children, all with good eyes.

2. John Adolphus, coralliform cataracts. Case published by Mr. Marcus Gunn. Three children (V, 2, 3, 4), of whom the eldest had *lamellar* cataract and was operated by Mr. Walter Sinclair at Ipswich; she died of diphtheria æt. 7. The second (V, 3) had "white cataract like his father" and died in childhood.

B. Children of III, 2—

3. William (Ipswich), cataracts operated (needled) by Mr. Morton at Moorfields in 1892–93, when patient was aged 17. Result fairly good. Cataract described as "congenital," and before needling the lens showed "opaque pearl-like bodies" towards centre with clear periphery. In 1905 this man has 3 children (V, 5, 6, 7) reported to have good eyes.

4. Arthur, cataract; lives near Manchester; it is not known whether he has been operated or not.

5. James (Ipswich), cataract. Has not been operated. Has 5 children, of whom first-born had lamellar cataract. See footnote to p. 219.

C. Children of III, 11—

16. Cordelia, first-born, and daughter, of III, 11, good eyes. One child, also with good eyes (V 9).

17. Emma, had good eyes, died æt. 3½ years.

18. Hebron, cataract, died æt. 1½ years.

19. Emily (Mrs. Faulkner, notes M. O. P. 1,219), no cataract. At æt. 20 had a large choroidal exudation in R.; had previously had abscess over R. lower jaw leaving depressed scar; lost all her teeth about æt. 18. No evidence of hereditary syphilis,

? tubercle. Seen again January, 1905, æt. 40; nothing fresh. Has had 3 children (V, 10, 10*a*, 11), all of whom have good eyes.

20. Miscarriage.

21. Hebron the 2nd; cataract, both eyes operated æt. 5 or 6. When I saw him in 1883, aged 18, V with + 10 D = 6/18 in each eye; January, 1905, aged about 40, still sees fairly well. Has 4 children (V, 12 to 15), of whom the eldest has cataract (see below); it is believed that the youngest has cataract also.

22. Victor, cataract. One eye operated at æt. 3, inflamed and shrunk, other eye not operated, and with it he still gets on tolerably well at æt. 38 (1905). Married, but no children.

23. Arthur, had cataract and was operated at æt. 2; died æt. 4.

24. Ada, cataract, no operation has been done. In 1893, when she was 24, I found V = 5/60. She has married since then and has 2 children, of which the elder (a girl), now living in Wales, is reported to have cataract (V, 16). Teeth of IV, 24 good, except that the lateral incisors were absent at æt. 14.

25. Kate, cataract, no operation. The condition, which is exactly like the other coralliform cases, was the same in 1905 when she was 32 as when I first saw her about 20 years before. Can see large print; teeth good, no defect of enamel. Unmarried.

26. Arthur, cataract; has not been operated. Married; no children (1905).

Generation V—

A. 2 and 3. See above under IV, 2.

B. Children of IV, 5. See IV, 5, and footnote to p. 219.

C. Children of IV, 21—

12. Sidney Cross, first-born of IV, 21, cataract of the same form as his father (IV, 21) and paternal grandmother (III, 11). I operated on the R. in March, 1896, and January, 1897, at æt. 5, discission followed by extraction. Ten days after the extraction the wound reopened from extensive intraocular hæmorrhage, and the eye was lost; it is believed that he accidentally struck the eye. V. before operation was 6/60. L. not operated, still sees usefully at the age of 15 (1905).

D. Children of IV, 24—

16. Daughter of IV, 24, reported to have cataract.

CASE 58*a*.—Mr. Fisher's case, which will be published in the Ophthalmological Society's Transactions, 1905–6, was briefly as follows:—

Miss P. G., nurse, V. always defective; R. cataract needled when æt. 20; "cholesterine came out;" irido-cyclitis and secondary glaucoma. L. typical axial or coralliform cataract, and lately general haze; now æt. 48.

She is youngest of 7; No. 6 (male) also had "congenital" cataracts, and had one eye operated when young without success; the others (Nos. 1 to 5) have good eyes, are all married, and have numerous children, none of whom have cataract. The mother of Miss P. G., who had the 7 children, had cataracts, and had one eye operated with success when æt. 48. P. G.'s father good sight. Three of P. G.'s grandparents known to have had good sight; the fourth she knows nothing about. No consanguinity; father Scotch, mother North of England.

CASE 58*b*.—Since the paper was written, I have obtained notes of another case, probably of the same kind.

Dobson family (St. Thomas' Hospital, 1884); 3 generations. In Generation I the mother was born with cataracts; one of her daughters (II) was similarly affected. The latter (II) had several children (Generation III), of whom 5 were cataractous, viz., first-born, girl, operated unsuccessfully; 2nd (girl), seen æt. 18, with white anterior polar and nuclear congenital cataract, and 3 others; sex and exact places in the childship not specified. No further particulars.

CASE 59.—Miss C., æt. 26 (20, 208, 1890). R.n., Hm. 1, 25, D. L. dense opacity of axial part of lens passing from anterior pole back deeply into lens; there are blunt, or knob-like projections from the axis, like those described in Case 58. Cataract believed to have been present at birth. Enamel of incisors somewhat deficient at cutting edge.

Miss Ruth C., 13 in 1887 (=16 in 1890) (14,163). L. lens shows a small speck just above posterior pole. Convergent squint usually of L., but almost alternating.

Both eyes emmetropic, and V. normal. History of fits. Teeth show defective enamel.

CASE 60 (Fig. 29) (Knies) [13].—Mixed axial and lamellar cataract in three generations.

1. Seen in 1875 with shrunken tremulous cataract; had been blind 21 years.

2. Daughter of No. 1, æt. 36 in 1875. Incomplete *lamellar* cataract. She had 6 children, all carefully examined and described by author; 4 of them had definite cataracts, partly lamellar, partly axial. In the other 2, the eyes, though clear, showed irregular refraction, which was not attributable to the cornea, and was therefore assumed to have its seat in the lens.

3. William, æt. 14½ (in 1875). See Author's Pl., Figs. 1 to 5.

4. Catherine, æt. 13; good eyes.

5. Margarette, æt. 11 (author's Fig. 8).

6. Clara, æt. 9; good eyes.

7. Jacob, æt. 7 (author's Figs., 6*a* and 6*b*).

8. Adam, æt. 3 (author's Figs., 7*a* and 7*b*).

No consanguinity of parents. No history of convulsions in any of the children; teeth perfect in all; no skull deformities nor developmental defects. Intellect bright in all.

III. *Familial Lamellar Cataract.*

Lamellar cataract usually affects only one member of a family or stock. But exceptions to this rule are not very rare, as the examples mentioned below will prove; indeed, according to the authors of some systematic treatises, heredity is common in this form.

I have been able to collect particulars, more or less complete, of 19 families, 6 cases being my own and 13 published by others.

In 8 families only 1 generation was affected, but as

1 of these families had cases in 3 sets of cousins, we have really 11 sets of siblings. They contained 28 cases—13 males, 15 females.

In 6 families 2 generations were affected, yielding in all 25 cases—9 male, 9 female, sex not stated, 7.

In 2 families cases occurred in 3 generations; in all 10 cases—4 male, 6 female.

In 2 families the cataract occurred in 4 generations; in all 12 cases—1 male, 11 females. The great excess of females in this group was due to 1 family, in which all the 7 affected members were female; the cataract is described in these 7 cases as "incomplete lamellar" (Galezowski's [21] case).

The total number of cases amounts to 76—27 male, 42 females, sex not stated 7, or omitting Galezowski's [21], probably atypical case, 27 males, 35 females. The total number of children in 12 of the childships was 67, with 32 cases of cataract.

1. In the 10 families where 2 or more generations suffered, descent was continuous in all.

Only in one or two instances do the records show whether the affected children were successive births or not.

2. Descent was through the mother in 13 generations, through the father in 6.

Descent was to the same sex in 13 generations, to the opposite sex in 8. The mother transmitted to both son and daughter in 2 of this total, but transmission from father to both son and daughter occurred only once.

As to the occurrence of fits, absence of enamel from the permanent incisor and first molar teeth, and defective intellect, the cases of familial lamellar cataract do not appear to differ materially from ordinary ones. In several cases the cataract is noted as being "small" or "very small." On all these points, however, much more material must be collected before any deductions can be made.

The following are the cases I have collected or seen :—

CASE 61.—Saunders [1] (1811) published a case which, from his description and illustration, was undoubtedly typical lamellar cataract in 3 brothers and 1 sister.

In the same place he mentions 3 other familial cases, but, as he gives no description of the opacity, we cannot say positively that these cases were of the lamellar kind.

CASE 62 (Fig. 30).—Storbeck's [14] case of familial lamellar cataract is very complicated, and apparently involves consanguinity on both sides, and in more than one generation; I find it impossible to unravel some of the kinships.

It deals with 7 cases of lamellar cataract, in 3 sets of siblings, containing 18 children. All the 18, so far as I can make out, are of the same generation, and all descended from a brother and sister, who had good eyes, and were grandparents to the affected generation. In the youngest subject (Generation III, No. 18), a child, æt. 14 months, the cataract was diffuse in one eye, and typically lamellar in the other. In another, æt. 22 (Generation III, No. 2), one eye showed a double shell of opacity and opalescence of the cortex, whilst the other eye contained a simple, rather small, lamellar capacity. All the others had typical lamellar cataract in both eyes.

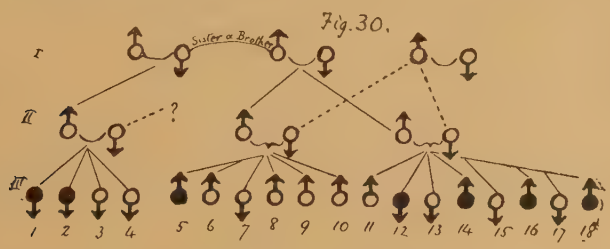

CASE 63.—Hirschberg [50] operated on a girl, æt. 15, who had double-layered lamellar cataract of both eyes. Her mother had complete uncomplicated cataract in one eye, and congenital strio-punctate cataract in the other.

CASE 64.—In the same paper he narrates the case of a child, æt. 5, with double cataract, whose father, now æt. 30, had suffered from cataract since the fifth year of life, and had been operated upon by von Graefe at the age of 20; whilst a brother

of the father, now æt. 32, who had had iridectomy in 1864 by von Graefe, was now found by H. to have lamellar cataracts.

CASE 65.—In a third family, H. found lamellar cataract in both eyes of a child, æt. 1 year, and ascertained that cataract becoming complete at the twentieth year of life had occurred in the 2 previous generations.

CASE 66 (Fig. 31).—Galezowski[21]. Cataract in 4 generations, proved to be of lamellar type in the last 2 generations. Females only.

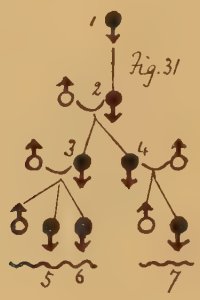

1. Operated for cataract.
2. Operated for cataract.
3. The patient, "incomplete zonular cataract."
4. Sister of No. 3, also patient of Author, with "incomplete zonular cataract."

5 and 6. Daughters of No. 3; both with cataracts like their mother's in character.

7. Daughter of No. 4, with cataract resembling her mother's.

CASE 67.—In von Arx's[22] dissertation on the Pathology of Lamellar Cataract (1883), giving particulars of 189 cases in Professor Horner's practice, between the years 1865 and 1873, Nos. 100 and 101 were siblings, æt. 37 and 38 respectively, and both giving a history of convulsions. And in his No. 71 (a girl, æt. 8), the father probably had similar cataract.

CASE 68.—Davidsen[10] saw lamellar cataract in both eyes of two brothers and a sister, æt. 31, 29, and 24 years respectively. (His cases 1, 2, and 3.)

CASE 69 (Fig. 32).—Hosch[30] (1897) published the following:—

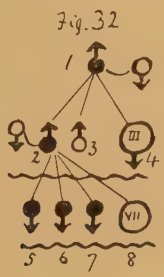

1. Paternal grandfather; an only child. Reclination operation by a travelling oculist, æt. 8; good result in one eye, moderate in other.

2. Adolf W. One of five, but which one not noted. Born (in 1843) with cataracts, diagnosed as lamellar by Horner when æt. 38, at which time artificial pupils were made. Teeth slightly "rachitic."

3. Only brother of No. 2. Died, æt. 4.

4. Three sisters; good eyes. Have between them 14 children, all with good eyes.

5. Sophie W. Born 1872; six toes to each foot. Walked at 12 months. Dentition normal. Cataracts seen by mother, æt. 2 days, by Horner, æt. 6 weeks, and again 6 years, and had not increased; diameter of opaque shell about 4 mm.

6. Elsie W. Born 1882. Cataract seen by mother just after birth. No fits. No rickets. Lamellar cataracts with clear cortex.

7. Anna W. Born 1885. History and condition same as Nos. 5 and 6. Double shell of lamellar opacity.

8. Seven others, free from cataract.

CASE 70 (Fig. 33).—Horovitz's Case[33], 1903, of Hereditary Lamellar Cataract.

1. Frau D. Lamellar cataract. Diagnosed by Hirschberg in 1888, when patient was aged 50. Had three children, two of whom had cataract.

2. Clara. Diagnosed 1874, æt. 16. No trace of rickets.

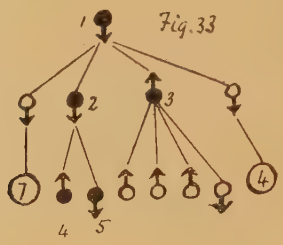

3. Eugen. Lamellar cataract diagnosed by Hirschberg in 1898, when patient was aged 35. Had three children, two of whom had cataract.

4. Arthur. Diagnosed 1885, æt. 4; born when Case 2 (his mother) was æt. 23. Rickets of legs; teeth good.

5. Martha. Diagnosed 1891, æt. 6. No traces of rickets, no convulsions.

CASE. 71. S. family. Ages as in 1890. Lamellar cataract in second and third members of a childship of six.

1. Mr. C. R. S. (9, 37). 34 in 1890. Em. V. 6/6. Darkish striped choroids. Fair hair and skin.

2. Jane. (17, 81.) 30. Lamellar cataract. Defective intellect. "Mercurial" teeth. Many infantile fits.

3. Florence. (20, 44). 28. The faintest possible degree of lamellar cataract. "Mercurial" teeth.

4. Edward. (3, 139). 27. My., 5 D., æt. 16. "Mercurial" teeth. No fits. V. 6/9 corrected; no note of examination of lenses.

5. Hermann. (4, 127). 26. My., 3·5 in R.; Em. in L., æt. 16. Fair hair. No other note.

6. Oscar. (10, 199). 24. My., 2·5 6/6 part, æt. 19. Very fair hair and white skin, but very dark, striped choroids. The mother has light flaxen hair, slight H. and V 6/6.

CASE 72 (Fig. 34).—M., sister and brother. (3, 21). In this case Nos. 3 and 7 in a family of seven had small lamellar cataracts, diagnosed in each case at æt. 14. Incisor teeth very good in both patients, and no history of infantile convulsions in either patient:—

Fig 34

1. Third born, Miss M., æt. 14, 1878, when cataracts diagnosed (1890, æt. 24, and in good health).

2. Girl. Died æt. a few weeks.

3. Seventh and last born; Charles, æt. 14, 1890, when cataracts diagnosed.

The other four living and with good sight in 1890.

Case 73.—M. (17, 60). Family of four sons, daughters not mentioned.

1. Lamellar cataract operated, æt. 13, æt. about 21 when seen by me. Bad teeth and history of convulsions.

2 and 3. No cataract; perfect sight. Good teeth. No convulsions.

4. Cyril M., æt. 16. R., – 9 6/24; L., – 3 6/18. Lamellar cataracts, faint and rather large, but opacity more dense at posterior pole. Had convulsions, and incisors are deficient in enamel.

Case 74.—T. O. P., I, 95. Jessie Hawkins, æt. 17. June, 1878.

Very small stationary lamellar cataracts. R. myopia, 10 D., L. about 10 D.; V. about 6/60. Teeth perfect.

Patient is 7th of 8 born; Nos. 1 and 8, both male, said to be short sighted.

Artificial ps. improved V. considerably (6/24). In 1898, M. still 10 d., and V. same.

M. I. P., 1898. Patient (now Mrs. Harrison) brings her son (æt. 12) with diagnosis of "Lamellar Cataracts," but the descriptive notes say "irregular axial opacity from centre of lens to posterior pole." Small myopic crescent. V. 3 months after removal of R. lens and secondary operation + 10 4/60. Enamel of teeth defective. Marked nystagmus. Ps. n. Is second born and only living of three. No. 1 said to have had one eye affected.

Case 75, Poulton family (T. I. P., 1882. Nos. 334 and 335). —Lamellar cataract in two sisters and a brother.

1. Elizabeth, æt. 13 in 1882 (= 23 in 1892).—Small, very dense lamellar cataracts, smaller than the ordinary undilated ps.; projecting spokes, cortex otherwise clear. Both needled and let out, and did well. Teeth "mercurial." Screaming convulsions in teething, and took many powders. Always delicate.

2. Ethel, æt. 7 in 1882 (= 17 in 1892). Rather dense lamellar cataracts; no note of size. Needled and curetted, evacuation same time as No. 1. Did well. Was treated for fits in infancy.

3. William, æt. 12 in 1892, large, dense, lamellar cataracts, 7 to 8 mm. diameter, with spicules. V. fingers, 6. Shy and nervous. Teeth "mercurial." Was treated as O. P. St. Thomas's for fits, æt. 8 months, and seen by me for eyes, æt. 14 months.

No note of other children nor of parents.

Case 76 (Fig. 35).—Pickett family. (I. P., 1883, No. 250):—

1. Had cataracts.

2. Bad sight as a child, and consequently learnt but little at school. Operated for cataract, æt. 30.

3. Mrs. Pickett, æt. 40 in November, 1883. V. never good enough to allow of reading newspaper print; getting worse, up to 8 years; now (1883) letters of 20 J.; sharply defined anterior and posterior cortical spokes and "indications of clear margin as in lamellar." L. needled and suction; good result. Teeth very bad, most of upper ones gone. No history of fits.

4. Sister of No. 3, V. always defective; operated for cataracts, æt. 16.

5. Louisa P. Daughter of No. 3, æt. 10. Small lamellar cataracts just filling moderately small pupil; no spicules, cortex

quite clear, but rather too visible. Double iridectomy down in. Teeth not mercurial.

Pedigree shows only those who had cataract.

CASE 77 (Fig. 36).—Bresgen [40] :—

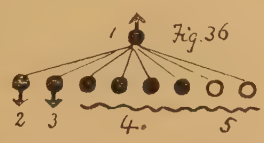

1. Aged 58. Cataract R. perinuclear; L. recently complete; sight bad in both eyes all his life. Of his 8 children, 6 had cataract.

2. Eldest daughter, æt. 25; could never see enough to read or write. Now L. cataract and R. total cataract, which has become rapidly complete during the last year.

3. Second daughter, æt. 23, not able to read or write since æt. 5, owing to lamellar cataracts with central capsular opacities in addition.

4. The four remaining cases, no details.

5. Two who had good eyes.

CASE 78.—E. Müller [85] records in great detail the particulars of a peculiar mixed lamellar and axial cataract in the 3 youngest of 5 sisters, Nos. 1 and 2 having good sight. Those affected were No. 3, æt. 30 at the date of record; No. 4, æt. 29, and No. 5, æt. 24. The mother, according to the history, was also probably affected.

An excellent half-schematic figure is given of the disposition of the two types of opacity in one of the affected lenses; this shows that Müller's cases were allied with those published by Knies (Case 60, p. 225).

CASE 79.—Mary Ann Horley (T.O.P. letter), æt. 49, June, 1883. Her son is under care for lamellar cataracts.

Her own sight gradually failing 20 years; now (1883) 20/O; R. letters of 18 J., L. letters of 14 J. Cortical cataracts, close beneath anterior capsule, in form of fine dots, and large and small spokes; all parts of surface of cortex affected, except anterior pole, which is quite free.

CASE 79*a*.—Von Hippel (according to Daust [45]) knew of a mother with lamellar cataract, 3 of whose 5 children were similarly affected.

Cases 84 and 85 should be included as lamellar.

Residual Cases.

In cases recorded many years ago, it is often impossible to say what form the cataract took, although in other respects many of these records are very valuable.

Such are, for instance, Maunoir's case, published in 1833; Dyer's in 1846; Armaignac's in 1869; and Baudon's in 1877. In each of these cases 4 generations were attacked.

The two former are fairly complete.

In Maunoir's [4] case 4 generations suffered; 2 members of the 2nd generation transmitted the disease, one of them being unaffected, an instance of discontinuous inheritance.

Dyer's [5] case also included 4 generations, and the statement is that only the males suffered. Descent was continuous, and in only one line, and the childships were large.

In Armaignac's [19] case, also of 4 generations, descent was continuous, and in both the 3rd and 4th generation two childships suffered; some of the childships were large.

Baudon's [15] case, of 4 generations, shows the same features as Armaignac's—continuous descent, 2 childships affected in the 3rd generation, and rather numerous children.

Some, *e.g.*, Cases 84 and 85, were almost without doubt lamellar, whilst one (97), Gjersing's remarkable case, should have been placed in the præsenile group, after Case 27.

CASE 80 (Maunoir), Fig. 37:—

Cataract in 4 generations, occurring earlier in the last generation.

1, 3, 4, 8, 9, all operated for cataract. Ages not stated.

8 and 9 were paternal first cousins of 7, but their sexes and exact parentage not stated.

6. Several sisters of No. 7, good eyes.

7. Cataract formed at æt. 30; no note as to when complete or whether operated. Both her parents were free.

10. One of 4 children of No. 7 was born with cataract; no details.

CASE 81 (Dyer), Fig. 38:—

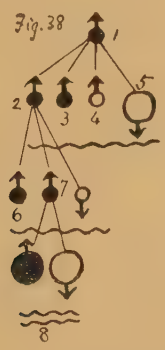

A form of congenital or infantile cataract, becoming worse in later life, males only; 4 generations affected.

1. Operated for cataract, æt. 54, and saw well till death some years after. "V. bad from childhood." Had large family, including "several" daughters (Fig. 38, No. 5); none of the daughters affected.

2. Operated for cataract, æt. 62 (1846); had been blind since æt. 40, and V. had always been "misty."

3. Quite blind; age not given.

4. Died young.

5. "Several" daughters, all free.

6. Cataract forming (1846); must have been middle-aged then.

7. Apparently in the same state as 6.

8. "Large family" in which all the sons have partial

cataract and all the daughters are free. These siblings seem to have been children at date of record (1846).

The following Case (82, Fig. 39) by Armaignac, in 1881, though incomplete in some particulars, is very striking even as it stands :—

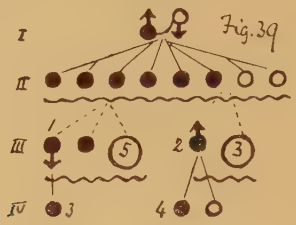

In Generation I the father had cataract; he had 8 children, of whom the 6 eldest had cataract. Nos. 1 and 2 (Generation III) were children of 2 of the cataractous siblings of Generation II, but their parentage is not given more exactly.

III, 1. Mdlle. K.; never been able to guide herself. Æt. 29, double congenital cataract with normal pupils and good p.l. (implying that cataracts were complete). Microphthalmos, squint, nystagmus. L. extraction, complicated; secondary operation gave some improvement, but no result with glasses.

2. Male—first cousin of No. 1, no details except that he had cataract from birth.

3 and 4. Children of Nos. 1 and 2. In No. 4, the left cataract was complete, and was needled by Author at the age of 5 years with success. The R. was incomplete. Nothing said about operation on No. 3.

Only Nos. 1, 3, and 4 were seen. None of the cases in Generations I and II were seen.

Case 83 (Fig. 40) (Baudon), 1877 :—

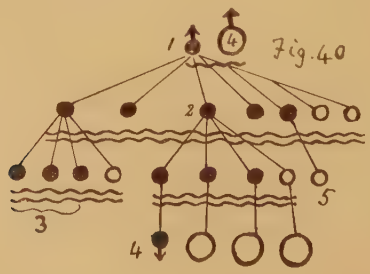

Congenital cataract in 4 generations. The kind of cataract not stated.

Information as to sex and order of birth incomplete.

The 1st case (No. 1) was in a man, who had 4 unaffected *brothers*; no mention of sisters.

The last case (No. 4) was a girl, seen by the Author when æt. 2 years, and needled by him. She was a granddaughter of the 3rd affected member of the 2nd generation (No. 2).

3. Three affected children of 3rd generation who were themselves childless at date of the paper.

5. A single child of 4th generation, unaffected.

CASE 84.—Adams[2]. Four siblings, of whom the first-born, a girl (Miss M. P.), had good eyes. The 2nd (girl) had "slate-coloured cataracts, with transparent edges" (doubtless lamellar cataract), when seen at æt. 13. The 3rd (boy), and 4th (girl, æt. 7) had "fluid" congenital cataracts; in the boy the opacity was discovered when he was a month old. All needled with success.

CASE 85.—Appenzeller's[24] Case 6 is that of a father and two sons. The father was born with cataracts, which were operated on about 50 years previously, and who still saw pretty well at date of record (1880), when his age must have been 60, less or more. He had six children, of whom Nos. 3 and 4, both male, were operated for lamellar cataract at the ages of 9 and 6 years respectively, in 1872. Nos. 1, 2, and 5 (males), and No. 6 (female) had good eyes.

No family history of eye disease or congenital anomalies.

CASE 86.—Adams saw two brothers from Dorsetshire, æt. 20 and 18 respectively, with shrunken congenital cataracts, which he needled with satisfactory results.

CASE 87.—Cahnheim[41] (according to Appenzeller) saw a peculiar posterior cortical cataract in the L. eye of a boy, æt. 6, and in other respects healthy, whose father had been operated for soft cataract, also in the L. eye. The affected eye in the boy was somewhat smaller than its fellow, and its iris darker in colour.

CASE 88.—Mooren[42] (according to Appenzeller) states that he operated for cataract on a mother, and on her infant that was born blind from cataract, with good results.

CASE 89.—Adams operated for "congenital" cataract on two children of a blind Welsh harpist, who was himself born with cataract.

CASE 90 (Fig. 41).—Froebelius[8] gives the following remarkable case:—

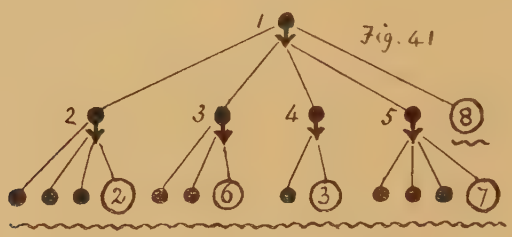

1. Had cataract, at what age is not stated. She had twelve children, of whom four (daughters) showed cataract in childhood. Their relative order of birth is correctly shown in the diagram, but the places of the remaining eight children are not given.

2 to 5. The four daughters who had cataract in childhood. It is especially stated that the husband of No. 2 had good sight, and came from a family free from any history of cataract; no note about the husbands of 3, 4, and 5.

2. Had 5 children, of whom 3 had cataract.
3. „ 8 „ „ 2 „
4. „ 4 „ „ 1 „
5. „ 10 „ „ 3 „

It is stated that the cataract in the 3rd generation came on at an earlier age than in the 2nd generation. Sexes and order of birth of the 3rd generation not given.

CASE 91 (Fig. 42).—Adams records this case, in which 3 generations suffered.

In a family of 7, Nos. 1 and 2 were boys, and had good sight. Nos. 3 to 7, all girls, were all born with double cataract. No. 7 died in infancy, but Nos. 3, 4, 5, and 6 were seen by Adams

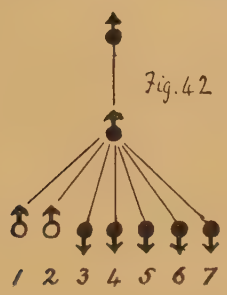

at ages varying from 19 to 7. All 4 had nystagmus, and the 3 elder had been previously operated, and showed residual capsular opacities, etc. No. 6, aged 7, had shrunken cataract in the R., and "fluid" cataract in L.; both eyes were needled, and did well.

The mother stated that the children's father (now dead) and grandfather were born blind with the same disease.

CASE 92 (Fig. 43).—Gerok[34] (Case 7) shows "congenital" or "juvenile" cataract in 4 generations, but with a break:

1. "Congenital" cataract.
2. Sex not given; good eyes.
3. Brother of 2; "congenital" cataract.
4. Boy, "juvenile" cataract at age of 8.
5. Sex not given, "juvenile" cataract at 5.

CASE 93.—Bastard[6] (according to Ullmann[20]) gives a case in which 15 cases of cataract occurred between the great grandfather and great grandchildren (4 generations).

A genealogical tree is stated to accompany the original.

CASE 94 (Fig. 44).—Lusardi [48]. Observation 3 (p. 33).

In a family named Lantlin, originally at Caen, the mother (Fig. 44, No. 1) has congenital cataracts, but sees well enough to go about alone. Two of her daughters and one son (2, 3, 4 on pedigree) have had cataract from birth, and Lusardi operated on one eye of one of the daughters, when she was 18, with success; she is married, but nothing is said about children. The other cataractous daughter, also married, has a little girl (5 on pedigree) born with cataract.

No details of the cataracts, nor of the other siblings.

CASE 95.—Lusardi [48]. Observation 2.

Congenital cataract in 6 of 14 children of parent Decamp (Belgian). The 6 cataractous ones not successive, "*i.e.*, first-born was cataractous, 2nd good eyes, 3rd cataractous, and so on." Two were twins, and of these the 1st had good eyes, the 2nd had cataract, and was still living at date, as also was one of his cataractous brothers. The 1st (of the twins) died æt. 17 months from kick on head by horse. The next birth to the dead one (*i.e.*, to the twins) had good sight, but also died æt. 17 months. Nothing as to sex or kind of cataract.

CASE 96.—Lusardi. Observation 4 is that of a man named Wattieaux, who had had cataract since the age of 30; his children, to the number of 5, were born with the same malady. On the same day L. operated on the father and the children, with good result.

Nothing as to sex of children.

CASE 97, published by Gjersing [51], really belongs to the præsenile group, and should be read next to Case 27, p. 201. Here no less than 20 cases of cataract occurred in 26 persons in 5 generations; 6 had been operated on at the date of the

paper. The condition does not appear to have been congenital, but it "anticipated" in a very marked degree in the succeeding generations. The family were farmers, and came originally from a small village. The cataract was double in all cases. It began usually as a small opacity at the centre of the lens, radiating streaks appearing later, but not always passing to complete opacity. In one, a child of 8, the cataracts were described as retrograde. Author considers that, though the cataract began earlier in the 4th generation, its rate of progress was decidedly slower than in previous generations. Only one member of the 4th generation out of a total of 15 seems to have been married. The entire family is stated to be very healthy except for the cataract. I find no mention of consanguinity.

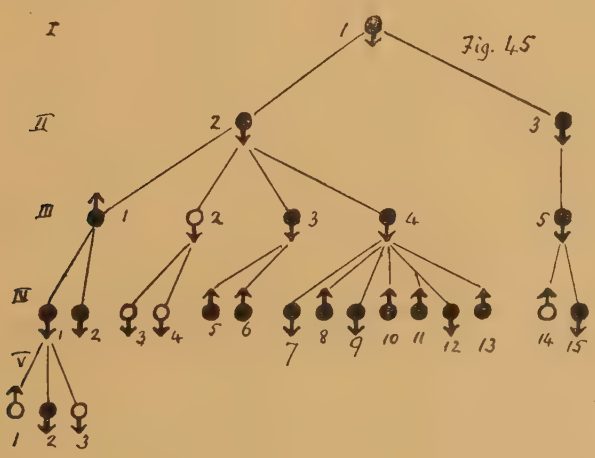

Generations I and II—

1. Woman, Nielsen, became blind in old age, almost without doubt owing to cataract. Died in 1840. She had 2 daughters, Nos. 2 and 3 of Generation II, both of whom became blind from hard cataract at the age of 40, and were operated on by the author by reclination, with permanently good result. No. 2 was born in 1801. No. 2, born in 1804, was alive and seeing well at the date of the paper.

Generation III—

Nos. 1 to 4, children of II, 2. In 3 of these sight failed at the age of 30; in the other, the eldest daughter, vision was still good at date of writing.

No. 5, daughter of II, 3, born in 1834, operated by the Author (reclination) with good result.

Generation IV—

Nos. 1 and 2, children of III, 1. Born in 1850 and 1852. Sight failed, about the age of 7, from cataract. No. 1 has 3 children. No. 2, unmarried.

Nos. 3 and 4. Born 1847 and 1852; both good eyes and both unmarried.

Nos. 5 and 6. Born 1848 and 1851. Both had cataract coming on about the age of 7. Both unmarried.

Nos. 7 to 13. Seven children of III, 4, all with cataract coming on about the 7th year. They were born between 1841 and 1863. No. 7 died, aged 9. It is not stated whether any of the others have had children. No. 8, born 1850, was operated by extraction in 1877 for cataract, described by Professor Hansen Grut as irregularly stratiform, with myopia and V corrected 15/200. Moderate success.

Nos. 14 and 15, children of III, 5. No. 14, born 1862, has good eyes. No. 15, born 1869, showed cataract at the age of 7 years; operated on by Professor Hansen Grut in her 12th year. Neither of these two old enough for marriage at date of writing.

Generation V—

Represented by three children of IV, 1, of whom the 2nd (the eldest *girl*), born in 1874, and aged 5 at the date of writing, showed in the R. eye diffuse cataract, in the L. eye a small central white opacity in the lens.

Concluding Remarks.

At the commencement of this paper it was suggested that differences might perhaps be found in regard to inheritance between the two classes, A—acquired or post-natal,

and B—congenital cataract, and throughout the paper various test questions have been put. Though the number of cases is small, especially in the several groups of the congenital class, there do appear to be some important differences between certain groups from the standpoint of heredity; especially between Class A, together with the lamellar group (III) of Class B on the one hand, and the other groups of Class B—the Complete Congenital Cataract (B I), and the Axial or Coralliform variety (B II)—on the other. For example, in Class A and the lamellar group together, we find about three females with hereditary cataract to every two males, whilst in the other two main groups of Class B the males are rather in excess in the comparatively small series available (70 cases). In this connection we may recall the statement on p. 199 that lamellar cataract has been seen in the offspring of a parent with juvenile acquired cataract. There seems also to be a marked difference as to consanguinity between the small group (B I) of complete congenital cataracts and all the rest, for in no less than four out of the ten families of B I the parents were first cousins, whilst in the whole of the remaining cases together there were only three or four known cases of cousin-marriage. But it may be doubted whether consanguinity is really so uncommon as it seems in Class A and groups I and II of Class B, for the fact is noteworthy that some of the families with the longest cataract pedigrees had been settled for long periods in remote country places where consanguineous marriages varying in degree and complexity would be likely to occur though the kinship might often be forgotten. For the present we can only say that consanguinity appears to be rare except in the group of complete congenital cataract.

In some respects, however, there is close similarity between the various groups. For example, the marked preference of the disease in certain stocks for one sex only (either male or female) is seen in several pedigrees of both classes. Again, the rule as to continuity of transmission

holds alike for both classes; and it follows from this that members of a cataract stock who are themselves exempt from cataract transmit good eyes to their descendants, so that in long pedigrees we find "strains" with, and "strains" without, cataract. Lastly, a study of the pedigrees and histories will show that the liability to cataract in a family does not lessen fertility, nor is there, I think, as yet any evidence that the subjects of congenital cataract (except in the little known group B I) are shorter lived than those affected by the senile and præsenile forms of the malady.

List of Authors.

1. 1811. Saunders. Diseases of the Eye, p. 134.

2*a*. 1812. Adams (Sir William). Ectropium, Artificial Pupil and Cataract, pp. 103 and 193, etc.

2*b*. 1817. Adams (Sir William). Practical Inquiry into the Causes of Failure of Depression and Extraction of Cataract, pp. 40 to 41, etc.

3. 1826.* Roux (J. A.). Thèse. Paris. Cataracte. No. 109.

4. 1833.* Maunoir. Thèse. Paris, No. 345. Professor Roux. Essai sur quelque points de l'histoire de la Cataracte. (Out of print.)

5. 1846. Dyer (S. S.). Provincial Medical and Surgical Journal, 1846, p. 383.

6. 1850.* Bastard. Thèse. Montpellier. Considérations pratiques sur la Cataracte. No. 25 (referred to by Ullmann, No. 20 below).

7. 1858. Streatfeild. R. L. O. H. Reports, vol. i, p. 104.

8. 1858.* Froebelius. St. Petersburg Medical Zeitung (quoted by Carreas y Arago, No. 23 below).

9. 1859.* Caussade. Thèse. Montpellier. Recherches pour servir à l'histoire pathologique de la Cataracte et de son traitement par l'aiguille. No. 5. (Out of print.)

10. 1865. Davidsen (Sophus). Inaug. Dissert., Zürich. Zur Lehre von Schichtstaar.

11. 1874. Hirschberg. Deutsche Zeitschrift f. prak. Medicin, 1874, p. 263. (= No. 31). August 1.

12. 1874. Klamroth. Inaug. Dissert. Greifswald (Professor Schirmer). Ueber Erblichkeit der Cataract.

13. 1877. Knies. Ueber den Spindelstaar. A. f. O., XXIII, 2,211.

14. 1877. Storbeck (A.). Inaug. Dissert. Magdeburg (Professor Laqueur). Beiträg 2. Lehre von Schichtstaar.

15. 1877. BAUDON. Recueil de Mémoires de Médecine de Chirurgie et de Pharmacie Militaires, III Série. T. 33, p. 646, 1877. Cataracte congénitale; observation curieuse d'hérédité. Repeated in Recueil d'Ophth., 1878, p. 9.
16. 1879. SICHEL (fils). Traité d'Ophthalmologie, pp. 878 and 919.
17. 1879. GRAEFE (ALFRED). Congenital Hard Cataract. Heidelberg Congress, 1879, p. 25.
18. 1880. JUST. Hirschberg's Centralbl., p. 8. Kernstaar im Kindesalter.
19. 1881. ARMAIGNAC. Révue Clin. du Sud-Ouest, Bordeaux. Reprinted in Mem. et Obs. d'Ophthalmologie pratique, 1889, p. 281.
20. 1881. ULLMANN (G.). Contribution à l'Étude de l'Étiologie de la Cataracte, Paris.
21. 1882, 1883, and 1885. GALEZOWSKI. Rec. d'Ophth., 1882, p. 719, &c.
22. 1883. ARX (MAX V.). Inaug. Dissert. (Professor Horner). Zur Pathologie des Schichtstaars.
23. 1884. CARREAS Y ARAGO. Hirschberg's Centralbl., p. 466.
24. 1884. APPENZELLER. Ein Beitrag z. Lehre v. d. Erblichkeit d. grauen Staars. Inaugur. Dissert. Tübingen (Professor Nagel), 1884.
25. 1888. BERRY. Ophthalmic Review, vol. vii, p. 1.
26. 1893. HIRSCHBERG. Centralbl., 1893, p. 225. The same family as in Horovitz (No. 33 below), but in less detail.
27. 1897. HIRSCHBERG. Centralbl., 1897, p. 271. Complete Congenital Familial Cataract.
28. 1897. PURTSCHER. Hirschberg's Centralbl., 1897, p. 198. Complete Congenital Familial Cataract.
29. 1897. SCHANZ (F.). Hirschberg's Centralbl., 1897, p. 264. Familial Juvenile Cataract.
30. 1897. HOSCH (Professor F.). Eine Schichtstaar-Familie. Festschrift E. Hagenbach-Burckhardt, p. 1.
31. 1899. STRICKER (LOUIS). The Crystalline Lens System, p. 235.
32. 1898. WESTHOFF (C. H. A.). Ann. d'Oculistique 119, p. 290. Congenital Familial Cataract.
33. 1903. HOROVITZ (H.). Inaug. Dissert., Berlin (Professor Hirschberg). Eine Schichtstaar-Familie.
34. 1904. GEROK. Deutschmann's Beiträge 3. Augenheilkunde, Band 6, p. 143, etc.
35. 1856. MÜLLER (E.). A. f. O., II, 2, 166.
36. 1875. BOWMAN'S statement is to be found in Darwin's Animals and Plants under Domestication. 2nd edit., 1875, vol. i, p. 453.
37. 1890. THOMPSON (TATHAM). Trans. Ophth. Soc., vol. x, p. 141.
38. 1880. DOR. Trans. Internat. Ophth. Congress, Milan, p. 152.
39. 1895. GUNN (MARCUS). Trans. Ophth. Soc., vol. xv, p. 119.
40. 1875. BRESGEN. Wiener med. Wochenschr., No. 33, p. 732.
41. 1875.* CAHNHEIM. Ein Fall von congenitaler Cataract. Inaugur. Dissert. Freiburg i. Br., 1875. Abstr. in Nagel, p. 184.

42. 1882. MOOREN. Fünf Lustren ophthalmologischer Wirksamkeit, p. 297.

43. 1827. LUSARDI. Mémoire sur la Cataracte Congénitale, 3rd édit., Bruxelles, 1827, p. 33, etc.

44. 1843. HIMLY (KARL). Die Krankheit u. Missbildung d. Menschl. Auges, Berlin, 1843, p. 239.

45. 1899. DAUST. Ueber Erblichkeit d. Angeborenen Katarakt. Inaug. Dissert., Kiel (Professor Völckers). (Daust gives the following, amongst other, additional references.)

46. *FUKALA. Beiträge z. Erblichkeit der Cataracta. Internatl. klin. Rundschau., Wien, IV, p. 1155.

47. *ZIEM. Mehrere seltene Fälle v. kongenitaler Katarakt; *HIPPEL (E. von). Path. Anat. d. Centr. u. Perinuclear Cat.

48 BOCK. Zehender's klin. Monatsbl., 1886, p. 227.

49. *RAMPOLDI. Cat. nucleo corticale in quatre individui della istessa famiglia.

50 1876. HIRSCHBERG. Beiträge z. prak. Augenheilkunde, p. 45.

51. 1878 or 1879. GJERSING. Ugeskrift f. Läger. R. 3, Bd. 26, No. 18 (Danish). I am much indebted to Dr. Ole Bull, of Christiania, for sending me a full MS. translation of this important case.

52. 1898. GUNN (DONALD). Ophthalmic Review, vol. xvii, p. 141.

Other references—

1811. GIBSON. Edinburgh Med. Jour., vol. vii, p. 308. Several children (of two sisters) idiotic and amaurotic and affected with cataract.

1838. *SANSON (L. J.). Leçons sur les Maladies des Yeux. 1ère Partie. Cataractes. All the children of a family said to have become cataractous about the 24th year of age.

*LUCAS (JAS.). Medical Observations and Enquiries, vol. vi, p. 250. Cataract in several of a family.

1905. HUNTER (T.). The Lancet, May 27 (I—1419). Cataract coming on in childhood in two cousins whose paternal grandfather had senile cataract.

1893. *FROMAGET. Gaz. Heb. Scien. Méd. de Bordeaux (quoted by Daust). Lamellar cataract in several generations.

* Denotes that the original has not been seen.

CAPSULAR COMPLICATIONS AFTER CATARACT EXTRACTION.*

By E. Treacher Collins.

The complications which may arise in connection with the lens capsule after the operation of extraction of cataract may be classified under two headings—

I. Those resulting from its adhesion to the extraction scar.

II. Those resulting from opacity occurring in connection with it.

I. *Complications Resulting from Adhesion of the Lens Capsule to the Extraction Scar.*

Microscopical examination of sections of eyes which have been operated on for extraction of cataract show that an adhesion of the lens capsule to the scar in the cornea, or at the sclero-corneal margin, may be due either to—

(*a*) An entanglement of a portion of the anterior capsule between the lips of the wound; or

(*b*) Agglutination of the capsule to the back of the wound by inflammatory exudate.

(*a*) I have three specimens of eyes lost after extraction of cataract in which the sections show an entanglement of a portion of the anterior capsule in the wound. In two of these it is the distal portion of the divided capsule which is so displaced, and in the other it is the central portion.

All three of these eyes were affected with severe serous irido-cyclitis after the operation, and in two of them sympathetic inflammation was excited in the fellow eye.

The clinical details of these three cases are briefly as follows:—

Case 1.—Joseph B., aged 64, admitted to Moorfields Hospital with senile cataract in February, 1888.

* Read in opening a discussion at a meeting of the British Medical Association, held in Leicester, August, 1905.

An uncomplicated extraction of cataract with iridectomy was performed on the left eye.

The patient suffered from a severe cough after the operation; there was some iritis.

Six weeks later there was hæmorrhage into the anterior chamber, and the tension became +2.

A paracentesis was performed.

Four days after the paracentesis, and 46 days after the extraction, iritis with keratitis punctata began in the fellow eye.

The increase of tension returned in the eye operated on, and it was excised 48 days after the extraction of the cataract.

CASE 2.—Mary K., aged 70, admitted to Moorfields Hospital with senile cataract in September, 1891.

An uncomplicated extraction of cataract with iridectomy performed on the right eye.

Operation followed by iritis, much chemosis and congestion.

Seven weeks after operation keratitis punctata noted and T+2.

Two paracentesises performed at an interval of 10 days.

A week later a needling of capsule, and an attempt made to divide it where it was adherent to the wound.

The iritis continued and the tension remained high.

Five months after the extraction of the cataract the eye was excised.

CASE 3.—Harriet S., aged 69, admitted to Moorfields Hospital with senile cataracts in both eyes in December, 1892.

An uncomplicated extraction of cataract with iridectomy was performed on the right eye.

She was re-admitted in February, 1893, and a similar uncomplicated operation was performed on her left eye.

She left the hospital nine days after this second operation, but was re-admitted seven days later with iritis and hypopyon.

Under treatment the hypopyon disappeared, but the eye remained watery and irritable.

Three months later the right eye became inflamed, there was well-marked keratitis punctata and the T. was full. At that time the left eye also had keratitis punctata, and the coloboma was filled with lymph and opaque matter, V. was = p. l. only.

The left eye was excised three months and nine days after the extraction of the cataract from it.

A microscopical examination of the extraction scar in all these three cases shows :—

A thickening of the sclero-corneal tissue in its vicinity, due to the spacing out of the layers of fibrous tissue, and some round cell exudate between them.

An elevation of the conjunctiva overlying it, due to a considerable accumulation of round cells beneath the epithelium.

A prolongation down, in finger-like processes, of the surface epithelium into the scar for some little distance.

A large accumulation of cells between the lips of the wound surrounding the entangled lens capsule. Nearest to the capsule many of these cells are of an epitheloid type; there are also giant cells of the Langhans type. Outside the zone of epitheloid cells are lymphocytes.

In Case 1 the entangled capsule occupies quite two-thirds of the depth of the wound; it is much corrugated, and the lips of the wound seem fairly firmly united.

In Cases 2 (Pl. I, Fig. 1) and 3 (Pl. I, Fig. 2) the entangled capsule occupies about half the depth of the wound, and where it is situated the lips are incompletely united. They gape apart, notwithstanding that in the one case five months and in the other more than three months had elapsed since the removal of the cataract.

The inferences which may be drawn from these appearances are as follows :—

That the entangled lens capsule lying between the lips of the wound has acted as a foreign body. It having produced around it just that arrangement of cells which is found around a foreign body implanted in the eye, such as an eye-lash, or the hair of a caterpillar in the affection known as ophthalmia nodosa, viz., a zone of epitheloid cells, some giant cells and lymphocytes.

That the presence of the capsule in the wound has

delayed healing, as shown by the gaping of its lips on the posterior surface, and the downgrowth of epithelium on the anterior surface.

That the delayed closure of the wound increased its liability to become infected by organisms from the conjunctival sac, and that the ensuing irido-cyclitis probably resulted from such infection.

Further, it is highly probable that a tendency to irido-cyclitis was predisposed to in these eyes by the constant drag kept up on the ciliary body through the entangled capsule in the wound.

In Case 1, where it was the central portion of the divided anterior capsule which had become entangled, the ciliary processes at the lower part of the eye were seen to be considerably stretched upwards, and the hæmorrhage, which made its appearance six weeks after the operation, seems to have proceeded from them.

(*b*) The writer has in previous papers* recorded the details of several cases of agglutination of the lens capsule to the posterior surface of the extraction scar by inflammatory exudate. It will suffice, therefore, to give here a summary of the results of his observations on such cases.

Either or both ends of a divided anterior capsule may become agglutinated to the posterior surface of the wound at the sclero-corneal margin after extraction of cataract, or the inflammatory exudate on the posterior surface of the wound may extend between the two lips of the divided anterior capsule and unite the posterior capsule to it.

The agglutination of the capsule to the wound does not delay its healing, as an entanglement in the wound does. The extraction scars which I have examined microscopically, where such agglutination has been present, have been firmly healed without any undue cell accumulation about them.

What it does is to considerably advance the position of the lens capsule from that which it normally occupies in the

* Trans Ophth. Soc. of U. K., vol. x, 1890, p. 108.

eye, and consequently to advance the position of the iris lying in front of the capsule.

In some cases the advance in the iris is sufficient to bring its root into apposition with the posterior surface of the cornea, so obstructing the exit of fluid at the angle of the anterior chamber and giving rise to glaucoma.

The fact that an iridectomy had been done in such cases might at first suggest that glaucoma would be unlikely to occur in them. The writer has found, however, that whenever the peripheral portion of the anterior capsule, or the posterior capsule, is adherent to the extraction scar, the angle of the anterior chamber in the situation of the coloboma has been closed by a small stump of the root of the iris, or by the most anterior of the ciliary processes, which has been held, or drawn forward, by the adherent capsule.

It is in by no means every case where there is an adhesion of the lens capsule to an extraction scar that increase of tension ensues. Clinically, many cases are seen with such adhesions in which a most satisfactory result has been obtained.

The more the advance in the position of the capsule, and secondarily of the iris, the greater the likelihood of the onset of glaucoma.

The more corneal a section is, the greater the advance of the capsule when adherent to it. For this reason, eyes in which the section is made near the sclero-corneal margin are less likely to be affected by glaucoma than those in which it is made in the cornea.

Sometimes in eyes with capsule adherent to the extraction scar, increase of tension does not come on until a subsequent needling operation. In some of these cases the writer has found that a fresh adhesion of capsule to the needle puncture has been produced which has still further advanced its position and brought about a closure of the angle of the anterior chamber by the root of the iris.

In other cases it may be that the congestion of the ciliary processes produced by the drag on them in tearing the capsule just suffices to push forward the root of the iris and cause

apposition of it with the cornea, to which it was previously closely approximated by reason of the adherent capsule.

When the capsule is adherent to the cornea, a fixed point is formed, against which the ciliary muscle has to pull every time it acts.

We know from experience in needling operations how any drag on the ciliary processes at once causes a blush of ciliary injection.

The writer thinks, therefore, that adhesion of the capsule to an extraction scar is a common cause why some eyes remain irritable and refuse to quiet down after operation.

Having described the effects which are liable to be produced by adhesion of the lens capsule to the extraction scar, it will be well next to discuss:

(*a*) How the complication may be avoided.
(*b*) What can be done to remedy the condition when giving rise to trouble?

(*a*) The operation of extraction of cataract without iridectomy is less liable to be followed by adhesion of the lens capsule to the wound than the operation of extraction with iridectomy. In the former the iris usually remains interposed between the divided capsule and the wound.

Adhesion of capsule does sometimes take place when the wound is a corneal one and no iridectomy is performed.

It is by no means very uncommon after the operation of curette evacuation for soft cataract where there has been no iridectomy.

The writer has recorded a case in which a cataract was extracted in its capsule without iridectomy, and where the anterior hyaloid of the vitreous was adherent to the wound. This adhesion drew forwards the iris and caused glaucoma.

In estimating the relative advantages of extraction of cataract with and without iridectomy, the greater liability of capsular adhesions to the wound should always be reckoned as one of the disadvantages of the former.

No method of opening the capsule as yet adopted seems

to exclude the possibility of adhesions, such as have been described, taking place.

If a piece of the anterior capsule be torn out with forceps, no adhesion of it from the corneal side of the wound can form. Entanglements of a peripheral portion of the anterior capsule or agglutination of the posterior capsule could, however, still take place. The writer has sections showing both these conditions from a case in which a portion of the anterior capsule had been removed in this way.

The difficulty in all measures for dealing with entangled capsule is the transparent character of the structure, which renders it impossible sometimes to see if an entanglement is present.

Mr. Swanzy, in his "Handbook on Diseases of the Eye," 7th edition, describes the following method which he employs to prevent incarceration of the capsule: —

"A bent iris-forceps is passed open between the lips of the wound, closed, and drawn gently out again. Frequently a tag of capsule will have been captured by the forceps, and is snipped off with scissors, or it may be that no capsule is caught. The forceps is then similarly inserted at an adjacent part of the wound; and in this manner the wound is searched from end to end for capsule. In about 25 per cent. of the cases a tag of capsule is found present."

Another method employed to prevent incarceration of capsule, and one which the writer generally adopts, is to pass the repositor used for tucking back the iris between the lips of the wound into the anterior chamber, in the situation of the coloboma, making much the same movement as that required for separating the iris from entanglement in the wound.

Simple agglutination of the capsule to the posterior surface of the wound is most likely to occur when there has been some delayed reformation of the anterior chamber which has allowed of their prolonged apposition. Anything, therefore, promoting a rapid closure of the wound tends to prevent agglutination of the capsule to it.

(*b*) The writer has seen a variety of operations performed for the purpose of relieving increase of tension coming on after extraction of cataract.

Sclerotomy, paracentesis, and needling of the capsule almost always fail. Sections of eyes which have been so operated on, which the writer has examined, show that they have not in any way affected the forward traction which the adherent capsule exerts on the iris, and that after all of them the angle of the anterior chamber has remained blocked as before.

An iridectomy, if performed on the opposite side of the eye to that at which the adherent capsule is situated, might open up the angle of the anterior chamber in that situation; it would, however, leave a large and unsightly pupil.

In two cases in which the writer himself has had to deal with this complication, he has attempted to cut through the adhesion of the capsule to the wound by a procedure similar to that described by Mr. Lang for the division of anterior synechiæ of the iris. He has used the same two knives as those employed by Mr. Lang, the one a Knapp's discission knife, the other a similar instrument with a blunt point. With the former he has made a valve-like puncture about the centre of the lower half of the cornea, then having withdrawn the instrument without allowing any aqueous to escape, he has introduced through this puncture the blunt pointed knife, passed it up to one extremity of the coloboma and made its cutting edge sweep across the whole posterior surface of the extraction scar.

In both the cases in which he has performed this operation the increase of tension was permanently reduced.

II. *Complications Resulting from Opacity Occurring in Connection with the Lens Capsule after Extraction of Cataract.*

A microscopical examination of eyes which have had the operation of extraction of cataract performed on them shows

that the membranes left which give rise to opacity may be classified under the following headings:—

(*a*) Retained lens substance.
(*b*) Wrinkling of anterior capsule and new growth of cells lining it.
(*c*) Adventitious fibrous tissue.

(*a*) After the extraction of a cataract any lens substance which is left is at first exposed through the opening made in the capsule to the action of the aqueous humour, but later the opening becomes sealed up by the proliferation of the capsule cells at its margins; any lens substance thus locked up, which if not originally opaque will have become so, is shut off from the dissolving fluid.

A lens, unless extracted in its capsule, is hardly ever removed so completely that some of its peripheral portions are not left which become closed up in this way. It is, of course, only when portions of lens substance are retained in the pupillary area that they give rise to any disturbance of vision, and opacity due to it is seen directly after extraction or within a few days of the operation. Lens substance retained in this way for several years will sometimes have calcareous matter deposited in it.

(*b*) The hyaline lens capsule left after removal of a cataract usually appears thicker than it does in the normal condition. This thickening is not due to any addition to its substance, for it is observed in eyes in which too short a time has elapsed since the removal of the lens to allow of any new growth. It is accounted for by the elastic character of the membrane, which is on the stretch and elongated when it surrounds the lens, but after its removal becomes shortened and thickened.

Though there is a certain amount of shortening, it is not usually sufficient to allow of the anterior part of the capsule lying smoothly in contact with the posterior part over any large area. The anterior part is generally thrown into several folds. These folds by themselves must tend to break

up rays of light and to cause some defect in vision; they are, however, nearly always associated with proliferation of the cells lining the capsule.

The epithelial cells lining the capsule in the region of the nucleated zone, when left after the extraction of a cataract, tend to proliferate, pass round, and then become separated from the capsule, as they do when the lens is intact. They do not, however, as they afterwards enlarge, become flattened out into lens fibres, but form large vesicular cells, sometimes oval, sometimes circular, in shape, this alteration being due to the lessened amount of pressure to which they are exposed.

The cells lining the more central portions of the capsule sometimes also multiply and develop into the same swollen, bladder-like cells, the capsule then being raised into prominences over little groups of them (Pl. II, Fig. 1).

A more frequent result, however, of the proliferation of the cells lining the central portions of the anterior capsule is the lengthening of them out into spindle shapes and into delicate fibres, which form a dense laminated tissue (Pl. II, Fig. 2).

It is with this sort of tissue that the opening left in the capsule after the removal of a cataract becomes sealed up, and with this sort of tissue the spaces left by the rucking of the anterior capsule most frequently become filled.

This tissue exactly resembles that which is met with in anterior polar opacities, which is produced in a similar way, and, like it, varies in its density according to the time which has elapsed since its formation. Occasionally when it has been in existence for a long time hyaline bands are met with between the laminæ.

It is the formation of this sort of tissue which gives rise to the opacity causing deterioration of vision coming on some time after the extraction of a cataract, and the longer it has existed the more fibrous, dense, and tough does it tend to become; consequently the more difficult to cut or tear with a needle.

(*c*) Adventitious fibrous tissue may form after extraction

of cataract as the result of cell exudation in iritis, on the front of the anterior capsule, or between the anterior and posterior capsule, or behind the posterior capsule about the hyaloid of the vitreous as the result of cyclitis. Sometimes a blood clot on the anterior capsule will form a sort of matrix in which fibrous tissue will develop.

In severe cases of iridocyclitis the anterior and posterior capsule may become embedded in fibrous tissue, forming a dense partition between the aqueous and vitreous chambers. It is the contraction of adventitious fibrous tissue on the surface of the anterior capsule, united to the extraction scar, that gives rise to an updrawn pupil after the removal of a cataract.

In an eye in which at the operation for the extraction of a cataract an opening in the lens capsule was made by tearing a piece of it away with forceps, and which, 11 years later, was excised on account of detachment of the retina which, it was thought, might be due to a new growth, sections showed that about two-thirds of the anterior capsule with its lining epithelium had been removed, the posterior capsule without any lining cells being left.

It is obvious that if a portion of the anterior capsule is removed in this way any cortical lens substance which remains in the region from which the piece has been torn cannot become re-enclosed away from the action of the dissolving aqueous humour; so that any opacity occurring after the removal of a cataract due to opaque cortical substance in which capsulotomy was thus performed would only be of temporary duration.

Further, no opacity could form in the region from which the piece had been removed due to the proliferation of the cells lining the anterior capsule.

Occasionally in cataractous lenses cells are met with lining the posterior capsule where normally they are absent. If these were present they would be left, both when the capsule is opened with forceps and with the cystotome. Whether if left freely exposed to the aqueous humour they

would be capable of proliferating and causing some opacity the writer is unable to say, but seeing that lens fibres which normally develop from them are dissolved by the aqueous humour, it would seem improbable.

The removal of a piece of the anterior capsule opposite the pupillary area with forceps would seem, therefore, to be a procedure likely to obviate two of the causes known to give rise to secondary opacities.

For this reason the writer determined in the year 1899 to try removing the anterior capsule with forceps in extracting 100 uncomplicated senile cataracts, and afterwards to compare the results, as regards the number of secondary needling operations required, with 100 cases of a similar character in which he had previously operated by opening the capsule with the cystotome.

In the two sets of cases the operation, except for the manner of opening the capsule, was carried out in a precisely similar way. An incision was made upwards at the sclerocorneal margin, comprising about one-third of its circumference, a conjunctival flap was generally made, and a small iridectomy always.

The use of forceps for the removal of capsule in extraction of cataract seems to have originated with Förster. Mr. John Couper employed forceps for this purpose for many years at the Moorfields Hospital, where the writer, when House Surgeon, had the advantage of watching his dexterous use of them.

The writer commenced by using forceps of the same pattern as those employed by Mr. Couper. These are constructed like a pair of iris forceps, with several teeth projecting and set at an angle on the lower surface of the part which enters the eye.

The arrangement of the teeth is such as to allow of their easily penetrating the capsule and obtaining a good grasp of it. More recently the writer has used forceps with teeth set and arranged in the same way, but smaller in the handle and with a gentle curve like those in use in Vienna.

As a general rule he has considered that a needling operation was required where the vision obtained with glasses after extraction was less than $\frac{6}{18}$ths.

Of the 100 cases operated on by him just prior to March, 1899, in which the capsule was opened by the cystotome, 47 ultimately required a needling, and in seven of these a second needling had to be performed.

Of the first 100 cases operated on since March, 1899, in which a piece of the anterior capsule was removed by forceps, only 15 required subsequent needling, no case required a second needling.

Of the second 100 cases in which a piece of the anterior capsule was removed by forceps, only four required subsequent needling, no case required a second needling, and a period of two years has now elapsed since the last of the second hundred extractions was performed.

The decrease in the number of needlings in the second hundred cases is probably due to an increased experience of the use of the forceps allowing of a successful removal of a large piece of capsule in a larger number of cases.

As the result of his experience the writer thinks it is best, after a small iridectomy has been performed, to introduce the capsule forceps closed to a position opposite the centre of the lens; then to allow the blades to separate to an appropriate extent, and while separate to depress them slightly backwards so that their teeth penetrate the capsule. On the forceps being again closed the capsule can often be seen to ruck up on the surface of the lens, a slight lateral side to side movement should then be made before withdrawing them from the eye. This lateral side to side movement serves to detach the anterior capsule and to prevent withdrawal of the lens in its capsule, which may occur if a pull outwards is at once made.

On two occasions the writer has removed the lens in its capsule by the forceps; in one case its removal in this way was followed by a slight loss of vitreous, in the other case no such loss occurred.

A fear is entertained by many that the use of capsule forceps might cause a displacement of the lens backwards into the vitreous humour. Doubtless such a displacement backwards is possible if an undue amount of pressure is made. The writer has now been using the forceps regularly for five years and no such accident has happened to him. Of the 100 cases in which the capsule was opened with the cystotome prior to March, 1899, vitreous was lost in five. Of the first 100 cases in which the capsule forceps were used in two only was there escape of vitreous, and in the second hundred cases there was escape of vitreous in three. The removal of a piece of the anterior capsule allows the cataract to present and escape from the wound with less pressure on the cornea than when the capsule has been opened with the cystotome. This probably accounts for the smaller percentage of cases in which vitreous was lost where the forceps had been employed.

In the tabulation of his cases another advantage which the writer has found to have resulted from tearing away a portion of the anterior capsule instead of simply lacerating it, is the better vision which the patients afterwards obtain. Out of the 100 cases in which the capsule was opened with the cystotome a record of the subsequent vision has been kept in 80, three cases obtained $V=\frac{6}{6}$ or $\frac{6}{6}$ partly without needling, and five others with a needling; of the three which had $\frac{6}{6}$ without needling, in two the vision two years later had so deteriorated that a needling had to be performed.

Of the first 100 cases in which the capsule was opened with forceps a record of the subsequent vision has been kept in 72, 24 cases obtained $V=\frac{6}{6}$ or $\frac{6}{6}$ partly without needling and two others after needling.

Of the second 100 cases in which the capsule forceps were used a record of the subsequent vision has been kept

Fig. 1.

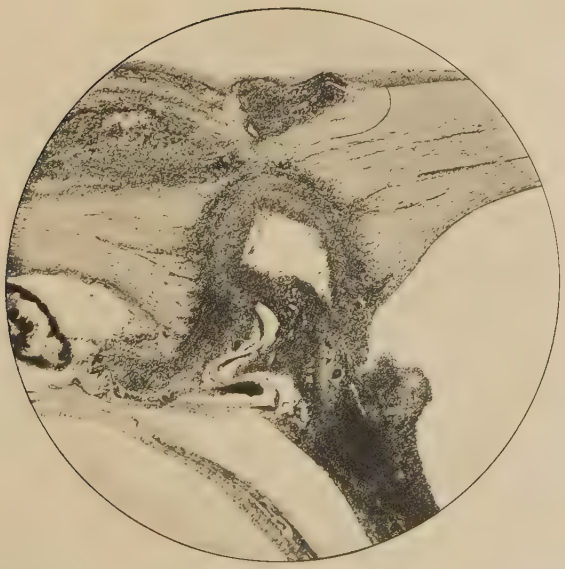

Fig. 2.

Bale & Danielsson, Ltd.

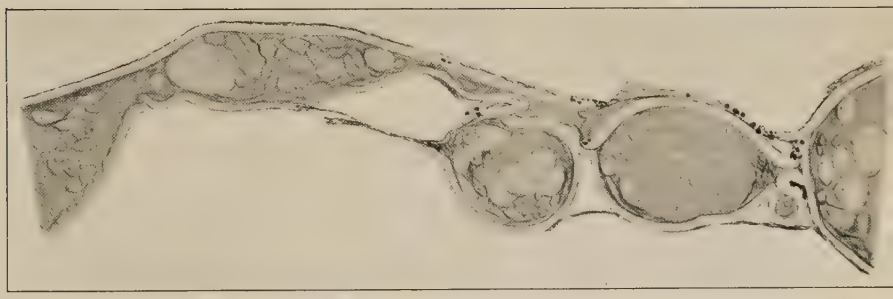

Fig. 1.



Fig. 2.

Bale & Danielsson, Ltd.

in 73, 27 of these obtained $V = \frac{6}{6}$ or $\frac{6}{6}$ partly without needling and one other with needling.

The writer doubts if by any other procedure for the removal of cataract full vision could be obtained in 25 per cent. of the cases with one operation.

Description of Plates I and II.

Plate I.

For the photographs from which the two figures in this plate have been reproduced the writer is indebted to Mr. E. Collier Green, of Derby.

Fig. 1.—Shows the extraction scar in Case 2. The external portion of the wound is seen to have united. There is some down-growth of the surface epithelium into it shown. The posterior part of the wound gapes widely, and the peripheral portion of the anterior capsule of the lens is seen lying between its lips, surrounded by much cell infiltration.

Fig. 2.—Shows the extraction scar in Case 3. The external portion of the wound has united. The lips of the posterior part are much swollen and infiltrated, they gape widely apart, and the peripheral portion of the anterior capsule of the lens passes forwards between them.

Plate II.

Fig. 1.—Shows the two layers of lens capsule after extraction of cataract, with large bladder-like cells, of subsequent formation, lying between them.

Fig. 2.—Shows the two layers of lens capsule after extraction of cataract, with laminated tissue lying between them, formed by proliferation of the lining epithelium subsequent to the operation.

OBSTRUCTION OF THE CENTRAL ARTERY OF THE RETINA.

By George Coats (Curator).

Cases of obstruction of the central artery of the retina in which a pathological examination has been made are still comparatively rare, and in some instances the descriptions or illustrations have been too meagre to allow of conclusions being drawn on various important points. The total number which I have been able to find in literature is 24. In addition, the diagnosis of "embolism" which v. Graefe instituted from his carefully-observed case, and which was probably correct for that case, has been shown by many writers—notably by Loring, Nettleship, and Priestley Smith—to be hardly tenable for other analogous clinical types. Within recent years, also, several cases have been reported from the purely pathological standpoint tending to diminish the importance of true embolism, and to raise into prominence other factors, such as endarteritis or thrombosis or a combination of these two. This point of view has been especially upheld by Haab and his pupils, and Reimar even goes so far as to say that there is no case on record in which the pathological examination has proved with certainty that a true embolism was the cause of blindness. This statement is much too positive, for there is no reason to doubt that embolism furnishes the best explanation of the pictures and descriptions given by Schweigger, Manz, and Marple. Case 1 reported below, and probably Nettleship's first case, also belong to the same category, and the clinical aspects of Gower's case make this diagnosis likely.

On the other hand, it is not to be denied that, both from the clinical and pathological standpoints, a strong case has been made out for endarteritis as the cause of obstruction in many instances—*e.g.*, in the cases of Elschnig, Wagenmann,

Michel, and Galinowsky. Thrombosis must, no doubt, be reckoned as a very important factor in these cases, but it is not a primary factor, and so far as the pathological evidence goes, does not occur as a causal agent except in association with disease of the vessel wall. A minor exception of no importance to the main question is furnished by a case of Siegrist's, in which blindness of one eye followed upon ligature of all the carotid arteries of the same side, and a coagulum was found in the ophthalmic and central arteries. Such a case, of course, stands in a class by itself, and need not enter into the discussion of the subject of obstruction of the central artery as ordinarily observed clinically.

Theoretically, certain other lesions might cause the same clinical picture, such as retrobulbar neuritis, spasm of the arteries,* hæmorrhage within the optic nerve or in its sheath, and tumours in the same situations; but none of these rests on any pathological evidence, and they will therefore not be further discussed.

In view of the comparative rarity with which such material is obtained for pathological examination, and in view of recent controversies as to the exact nature of the process involved, it seems well to publish and illustrate such cases where possible. The term "embolism" will be used in this paper in its strict meaning as a plug imported into the

* Spasm of the arteries has the support of certain analogies, notably the fine thread-like appearance of the vessels in quinine amaurosis, which has been supposed to be due to this cause. Narrowing of the retinal arteries from spasm has also been described by Raynaud in the disease which goes under his name, but the observation has never been repeated, and has been denied (by Panas) even for the case in which Raynaud described it. (See Raynaud, Arch. générale de Médicin, 1874; Panas, Des Maladies des Yeux. Panas was a colleague of Raynaud's, and examined his ophthalmological cases for him. The whole is quoted in Reimar's paper in Arch. f. Augenheilk, vol. xxxviii, 1899, p. 291.) It is possible that spasm may have played a part in some instances, but almost all the cases which have been pathologically examined have shown changes quite sufficient to account for the symptoms without calling in its aid. Records of spasm of retinal vessels observed ophthalmoscopically are always to be received with caution, as the condition is easily counterfeited when the vessels are badly filled from any cause.

central artery from some other part of the circulatory system, while the more general name "obstruction" will be used to cover all the processes above mentioned, which are usually included under the clinical term "embolism of the central artery."

CASE 1 was under the care of Mr. Doyne, to whom I am indebted for the material and the clinical notes.

Caroline M., æt 52, came first to Oxford Eye Hospital in October, 1892. The right eye had been divergent since childhood, and was amblyopic. The vision of the left was less than 6/18. Ophthalmoscopic examination showed cataractous changes in the periphery of both lenses. She was seen again in April, 1897, when vision had sunk in the left to the counting of fingers at four yards, and the lens opacities had much increased. In January, 1900, a preliminary iridectomy was performed on the left eye, from which recovery was perfect except that on one occasion there was slight hyphæma. On July 19th, 1900, a soft and sticky lens was extracted from the left eye. There was slight temperature for a few days afterwards, the lids were a little puffy and the pupil was dilated irregularly, but by August 11th the eye was quite quiet, and with correction she saw 6/18 and J.8. On October 2nd, 1900, a needling was undertaken for some capsular remains in the pupil. The eye remained perfectly quiet after this, but on the evening of October 6th the patient noticed, when the bandage was taken off, that she could see nothing. There had never before been any attacks of temporary blindness. On ophthalmoscopic examination next day the typical picture of obstruction of the central artery was discovered, with an interrupted stream flowing towards the periphery in the branch over the macula. Examination of the heart showed severe endocarditis, double mitral disease, and aortic regurgitation. A history was obtained of rheumatic fever when she was a girl. The urine contained no albumen or sugar.

No useful vision was ever recovered in the affected eye, but for a time she could see a "hole of light the size of a soup-plate" in the temporal side of her field of vision. This, however, was presently lost also, and the eye remained without perception of light. The disc became atrophic, with thread-like vessels. In

addition, a low form of iritis set in, with pain in the eye and brow; the pupil was irregular, and there were numerous posterior synechiæ; the tension was raised and new vessels formed on the anterior surface of the iris, large enough to be seen two feet away, and looking like hæmorrhages. Hyphæma occurred several times. In the hope of giving her a little vision, an extraction was performed on the right, amblyopic, eye, which had by this time also become cataractous, and this was so far successful that she was able to count fingers with it at one metre.

On December 15th, 1903, the patient died, and the left eye was obtained *post-mortem*—about 3 years and 2 months after the occurrence of blindness.

Pathological Examination.—The globe was hardened in formalin, bisected vertically, imbedded in celloidin, and cut in serial sections. The nerve was excised, and cut in transverse serial section from the intraocular surface of the papilla backwards through the lamina cribrosa. Macroscopically the pillars of the iridectomy coloboma and the lens capsule were adherent to the extraction wound. The corneo-iridic angles were occluded, and the disc was deeply cupped.

Microscopic Examination.—The changes in the anterior half of the eye may be briefly summarised. The lips of the corneal wound are separated by new-formed connective tissue containing uveal pigment, and by lens capsule. The latter penetrates right through, and lies close under the conjunctival epithelium. The stump of iris is closely adherent to the back of the cornea, and highly atrophic. There is adhesion of the root of the iris to the cornea also on the opposite side, so that the corneo-iridic angle is completely shut off. The iris itself is condensed and cellular, and its pupillary border is closely bound to the lens remains by a mass of new-formed connective tissue. There is blood in the anterior chamber. Where the lens capsule is not adherent to the corneal wound it has collapsed and enclosed some lens remains, as in a bag; these lens remains are calcareous. There has been some formation of fibres from the lenticular epithelium, as is seen in anterior capsular cataracts. On the anterior surface of the iris there is a layer of cellular tissue containing new-formed blood vessels, but as these are all empty they are not so striking as

might have been expected from the clinical description.* The ciliary body is highly atrophic on the side of the iridectomy, less so on the other. The choroid is much sclerosed and degenerated; there are a few inflammatory patches and some small colloid excrescences. Towards the anterior part there are some adhesions between the choroid and retina.

Retinal and Central Vessels.—For convenience of description, both arteries and veins are followed backwards from the retina up the nerve. The smallest retinal vessels show hyalin degeneration of their walls and obliteration of their lumina. Of the larger, many are collapsed and obliterated, apparently by fibrosis of their walls, but a certain number of them are fairly normal and contain a little blood. On the side of the cup the vessels, both arteries and veins, are highly sclerosed; the minute lumen, however, is lined by a single layer of endothelium—the process is not one of endarteritis, but of fibrosis. Some are completely obliterated, while others contain a few blood corpuscles or a homogeneous coagulum. At the bottom of the cup a single main artery is formed, and almost immediately above this the lumen becomes blocked by the mass shown in Pl. III, fig. 1. This mass is calcareous, and shows a vitreous fracture. In consequence of this it spoiled the knife in cutting the sections, so that it was torn out of some of the succeeding ones, and its exact mode of ending centrally cannot now be studied. It totally fills and over-distends the lumen of the artery where it lies, but it has no connection whatever with the surrounding tissues, which are quite free from any trace of inflammatory reaction. There has therefore been no attempt at organisation. A little slit at one side contains no blood corpuscles, and was probably produced artificially. With high powers the mass is finely granular, and shows no nuclei or remains of blood corpuscles. No endothelium can be detected lining the arterial wall. The entire mass is within the area of the lamina cribrosa. As mentioned above, a similar structure has evidently been torn out of the lumen in the succeeding sections, but just beyond the lamina this ceases to be the case, and the artery is, on the other hand, extremely collapsed and shrunken (Pl. III, fig. 2). Its walls can still be traced, and with

* This condition has been described and figured by Spicer and Parsons in Trans. Ophth. Soc., vol. xxii, p. 306, Plate XXII, fig. 1.

elastic tissue staining, the membrane of Henle can be made out, thrown into zig-zag folds. There is no lumen, but its situation is occupied by an almost homogeneous structure with a few nuclei in it, evidently slightly proliferated endothelium brought together, and adherent in consequence of the collapse of the walls. It has not the appearance of an organised thrombus, since the inflammatory processes necessary to organisation could hardly have left the different layers of the wall so intact and easily recognisable after so long a time. This condition of the artery persists unchanged till the end of the series of sections.

The central vein also shows very profound alterations. At the site of the arterial obstruction the vein is still in two branches, both of which have exceedingly thick walls. In one there seems to be a minute endothelium lined lumen, while the other appears to be entirely blocked. A little farther back this blocked division contains a small cellular organised mass, apparently an organised thrombus. Only a considerable distance up the nerve do these two branches unite to form the single central vein. This has enormously thickened walls, while the lumen is a mere slit (Pl. III, fig. 2). The process has evidently been one of thickening of the connective tissues of the wall—fibrosis—since the lumen is still lined by a single unaltered layer of endothelium. Farther back in the nerve this small lumen becomes entirely obliterated. In no part of the vein are any red blood corpuscles visible.

Retina and Optic Nerve.—The retina shows the changes which have always been found in these cases of obstruction of the central artery, viz., atrophy of the nerve-fibre and ganglion-cell layers, with good preservation of the outer layers which are nourished from the chorio-capillaris. Owing to the long time which has elapsed in the present instance since the occurrence of the obstruction the atrophy is very extreme. Hardly a trace of the nerve fibres is to be detected, while only here and there is a cell to be seen, which is probably not a ganglion cell, since it lacks the characteristic polyhedral form. There is no retinal œdema. The disc is steeply and deeply cupped, and the nerve is in the highest degree atrophic, consisting merely of a shrunken mass of connective tissue without any nerve fibres at all.

Briefly summarised, the pathological conditions found in the case may be stated as follows :—The extraction wound, not firmly healed on account of the intervention of capsule between its edges. Signs of old iritis—posterior synechiæ, new formation of connective tissue with vessels on the anterior surface of the iris, ectropium uveæ, atrophy, adhesion of the root of the iris to the back of the cornea with blocking of the filtration angle. In the central artery, at the level of the lamina cribrosa, a calcareous mass distending the vessel. Extreme collapse and secondary changes in the vessel walls, both in front of and behind this plug, with an organised thrombus in a main branch of the central vein about the same level.

Clinically, the case illustrates a very unusual and disconcerting complication of cataract extraction, but there seems no reason to regard the combination as other than accidental. The changes found in the anterior half of the eye fully account for the occurrence of glaucoma, and, therefore, the case is not analogous to certain others which have been described, in which glaucoma followed upon uncomplicated embolism of the central artery—a sequence of events which will be discussed more fully in connection with the second case.

With regard to the mass in the central artery there seems to be no reason to doubt that it was a true embolus, probably a calcareous nodule from the diseased aortic valves. There cannot have been any high degree of endarteritis in the arteries previous to the block, or they could not have collapsed so completely. The mass fully filled or overdistended the artery where it was situated, yet there was no intimate connection with the vessel wall nor any trace of organisation in spite of the long period during which it had remained there. It can, therefore, hardly have been a nodule of endarteritis or a thrombus. The absence of any organisation is probably to be explained by the fact that the embolus was calcareous when it reached its position, and was, therefore, incapable of cellular invasion. The

microscopical appearances were closely analogous to those found in the cases of Schweigger, Manz, and Marple, and it is noteworthy that in the first two of these cases there was aortic cardiac disease, while in Marple's case, though the condition of the heart is not mentioned, the patient had suffered from rheumatism. In all these cases a true embolism seems to offer the best explanation of the pathological findings, although it may be admitted that the same solution is not suitable or possible for some of the others. In spite, therefore, of recent opinions to the contrary, the occurrence of true embolism of the central artery may be taken as resting on a sound basis of pathological proof.

An interesting clinical point in this case was the preservation for a time of a little vision in the temporal part of the field, although the picture was that of complete obstruction. This is by no means uncommon in recorded cases, apart altogether from the occurrence of unblocked cilio-retinal or macular arteries. The preserved area is almost without exception on the temporal side of the field—on the nasal side of the fovea therefore. I have not met with a perimeter tracing to show its exact position; indeed, perimetry would be difficult to carry out in these cases, since the patient has lost central vision. But an observation of Fischer's is of interest in this connection. By noting on what part of the fundus the ophthalmoscopic image of a small flame fell, he found that the patient had perception of light only in an area of about one-third disc diameter around the papilla. The explanation at once suggests itself that the capillary anastomoses between the ciliary and central vessel systems in this region are capable of keeping up the nutrition of a small zone of retina in the immediate vicinity of the disc.* This raises the much debated question

* Two circles of anastomosis are described in this region: (1) A posterior, by branches from a circle of arteries in the sclera (circulus of Zinn); these have no corresponding veins. (2) An anterior, by branches from the choroidal vessels; these have corresponding veins. In both cases the vessels are little above the size of capillaries. (See Leber, Graefe Saemisch Handbuch.)

as to the amount of collateral circulation which may be established when the main artery is blocked. It is usually taken for granted that this is nil, and, indeed, for practical purposes and so far as the functions of the retina are concerned, it may be admitted that the central artery is an end artery. Yet it is a common observation that arteries which have been thread-like and almost invisible at the time of the occurrence of obstruction, become after a while decidedly better filled or even tolerably well filled. Afterwards, in the course of weeks or months with advancing atrophy of the disc, they again become small and frequently sclerosed.

This well-established clinical fact has given rise to very various conjectures as to its cause. The earliest explanation (Schneller) was that the obstruction was situated in the ophthalmic artery at the point where the central artery was given off, and that it was afterwards carried onwards so as to leave the central artery free to fill up again. While such an occurrence is theoretically possible, it must be admitted that it could only happen very exceptionally, and since the refilling of the arteries is the rule rather than the exception, the hypothesis must be discarded, more especially as no proof has been brought forward in support of it. Another supposition has been that the embolus gets broken up by the blood pressure behind it, and the pieces of it scattered among the retinal arteries, but this is probably impossible without some ophthalmoscopic evidence, evidence which is usually entirely absent.* Or, again, the theory of "incomplete embolism" has been advanced. The plug stops at a part of the artery which it does not completely fill, and the obstruction is made complete by spasm

* In a case of Hirschberg's, however, something of this kind probably really happened. In this instance there were the usual ophthalmoscopic appearances of complete obstruction with very small vessels. The case had been very frequently and carefully watched, and on the morning of the third day was much as at first. On the evening of that day, however, "as by a stroke of magic," all the vessels were normally filled again, except that there was an obstruction some distance out on the inferior temporal artery.

of the arterial wall. Afterwards this spasm relaxes, and the vessel may even become abnormally dilated owing to ischæmic paralysis. Hence a current is re-established. The weakness of this explanation lies in the supposition that a mass whirled along by a tolerably swift current will stop before it is brought up by the narrowness of the vessel lumen or by impinging against a bifurcation. Hence, the theory has been modified by supposing that the plug goes far enough to completely fill the vessel, but that the contraction of the arterial wall which it induces compresses and moulds it to a smaller size, so that when the spasm relaxes again a small lumen is left at the side. It seems probable, however, that secondary thrombosis would prevent re-establishment of the current. These explanations are highly theoretical, and rest on no clear pathological evidence.

Again, it has been supposed that if the obstructing mass were angular and hard—as, for instance, a piece of calcareous cardiac valve—it might lodge in the vessel but still allow some blood to flow past it. But it can hardly be doubted that in this case secondary thrombosis would soon make the obstruction complete. Canalisation of a plastic embolus or of a thrombus is also a possible means of refilling of the retinal arteries. Its occurrence has not been proved in the artery, but I have shown that it may occur in the vein.* In the cases now under consideration, however, the time which elapses before some circulation is re-established is usually much too short to allow of such an explanation. Mr. Nettleship has kindly placed at my disposal some notes of cases observed by him, which show

In spite of this refilling, vision was not greatly improved, the retina having probably been too long anæmic. In this case it seems likely that an embolus or thrombus had obstructed the central artery (probably already narrowed by endarteritis), and that it had suddenly given way at some time of heightened blood pressure, and been carried into the inferior temporal artery.

* R. L. O. H. Rep., vol. xvi, pt. 1, Case 2, p. 83. Another almost exactly similar case has since been published by Sidler-Huguenin, Arch. f. Augenh., November, 1904, p. 27.

that after complete obstruction of the central artery with total loss of sight, some re-establishment of the circulation (as tested by the possibility of producing pulsation in the arteries and by their refilling after emptying) may take place within $2\frac{1}{2}$ hours.

There remains the possibility that the refilling of the vessels is due to the re-establishment of a small collateral circulation. This also cannot be said to be proved for all cases, though there is evidence in its favour. The objection has been raised that if a collateral circulation is formed in this manner, it should go on enlarging until the vessels have reached their normal size, instead of which the vessels after a while again become small and sclerosed. But the amount of collateral circulation which the anastomoses around the nerve head are capable of feeding must be small, since the vessels are of little more than capillary calibre, and are, therefore, probably not capable of indefinite distension, especially on the occurrence of a sudden block. It is a sufficiently well-known pathological principle that a vessel wall tends to adjust itself to the amount of blood flowing through its lumen, not only by partial collapse, but also by thickening. Thus, when the central vein is blocked, not only is the vessel collapsed and with a small lumen higher up the nerve, but its walls are enormously thickened by increase of the connective tissue elements in them. This thickening of the wall decreases as the lumen of the vein gradually becomes better filled by the accession of collaterals. It cannot be a compensatory thickening to meet heightened blood pressure, since the pressure must be greatly lowered just above the block; it must, therefore, simply be due to adjustment of the vein wall to the small quantity of blood in it. The same process of vascular thickening occurs when the central artery is blocked, both in the retinal arteries and in the retinal and central veins, as the present case shows (Pl. III, Fig. 2). This is probably the reason for the final smallness of the vessels, even in those cases which have refilled fairly well after the primary block. The

pathological history of a case might be divided into three stages as follows:—(1) At first the arteries are thread-like from more or less sudden cutting off of the blood stream. (2) Later there is some refilling from the re-establishment of a collateral circulation—we are looking with the ophthalmoscope at a small stream in more or less normal arteries. It is to be remembered that the size of arteries ophthalmoscopically is not necessarily an indication of the amount of blood flowing through them. The velocity of the circulation must also be taken into account, and this cannot be noted unless it falls very far below the normal and indicates itself by visible streaming or beading in the vessels. It is possible, therefore, to have arteries of fair size yet conducting only a comparatively small stream of blood. (3) The last stage is that of the above-mentioned fibrosis of the vessel wall—we are looking with the ophthalmoscope at a small stream in thick-walled arteries, and this corresponds to the final stage of thread-like sclerosed arteries associated with optic atrophy in old cases of obstruction.

It is probable, however, that the freedom of the collateral circulation is subject to individual variation associated with corresponding differences in the clinical course of the case. There are several recorded instances (Schneller, Fischer, Wagenmann, Story) in which, after the picture of complete obstruction, there has been considerable recovery of sight, while on the contrary other cases have never shown any perception of light from the beginning. The usual explanation of these cases with recovery is similar to that given for cases with prodromal obscurations, viz.: there is narrowing of the lumen of the central artery from endarteritis, and if the general blood pressure falls from any cause —not necessarily low enough to cause fainting or cerebral symptoms—it may be insufficient to force the blood past the narrowed part, and the picture of obstruction of the central artery is produced. If, however, within a short time the pressure rises again the blood may force a passage, and

provided that the retina has not been too long anæmic, some vision may still be saved. This is no doubt the explanation of many, perhaps most of these cases, but it is also possible that in some instances the freedom of the collateral circulation, and the rapidity with which it can be established may have something to do with it. The good effects of massage in some cases and its entire inutility in others may also be related to the freedom of the collateral circulation.

The exact position of the block too, as Nettleship has remarked, would probably have considerable influence. If it were extremely far forward, on the inner side of the lamina cribrosa and just at the bifurcation of the vessel, the anastomoses would be shut out from participation because the block would be beyond them; but in this case it might happen that a macular branch was given off from the main artery central to the obstruction, which would preserve some vision by another mechanism similar to what occurs when a cilio-retinal artery is present.* On the other hand if the block lies within or central to the lamina cribrosa the anastomoses of the nerve head have full play. It seems possible that if the block is fairly far forward the superficial portions of these anastomoses will be especially dilated, and this may account for certain cases in which an anastomosis has been visible ophthalmoscopically in the form of fine networks around the papilla. Such networks are sufficiently common in cases of obstruction of veins, but after blocking of the artery they are very rare. I have only been able to find two in the literature, one by Nettleship, and one recently by Gonin. Mr. Nettleship has kindly allowed me to peruse notes and sketches which he has made of a third. These cases furnish strong evidence that some degree of collateral circulation is possible after blocking of the main artery. A

* It is wrong to attribute the preservation of a small triangular field on the temporal side of the disc in every instance to a true cilio-retinal vessel. In many cases this has been the cause (Nettleship, Lang, etc.); but in others the unblocked twig has undoubtedly been a branch of the central artery itself coming off higher than the obstructed portion (Hirschberg, etc.).

case reported by Lawson in which the arteries which were fine and thread-like on the disc suddenly swelled out to their normal size as they crossed its edge, also points in the same direction.

Further, and perhaps even better, proof is furnished by another class of cases—those in which the central artery has been divided with the optic nerve in optico-ciliary neurotomy or for the removal of tumours of the nerve. In these cases although the retina is anæmic at first, the vessels do not remain totally empty, but refill to some extent. A case of Schlodtmann's is of especial importance in this connection. In a case of tumour of the optic nerve the disc had been noted to be atrophic and the vessels of full size. The tumour and optic nerve were excised with preservation of the globe, by resecting the external rectus muscle. An ophthalmoscopic examination undertaken on the evening of the day of operation showed the vessels still of normal calibre, so that it may be supposed that even immediately after the operation they had not been totally empty. Microscopical examination proved that the artery had really been cut, but it had already been obliterated by the growth higher up the nerve, so that the collateral circulation was already in action when the nerve was divided. In another case in which the eyeball was enucleated along with the tumour, the overfilling of the collateral vessels in the nerve was proved microscopically. In these instances two factors were present which are absent in the class of cases which are now under consideration. They differed from embolism cases in that the obstruction was gradual and not sudden, and from cases of endarteritis or thrombosis in that the ciliary vessels, on which the re-establishment of the circulation depended, were probably normal or even distended. A similar case has been observed by Grüning. Restoration of retinal circulation after section has also been shown to occur in rabbits (Wagenmann) and cats (Leber).

Again the central vein is usually regarded as an "end" vein—a vein the obstruction of which is not compensated by

a collateral circulation, and clinically it undoubtedly is so, its blocking being followed by the well-known ophthalmoscopic picture and almost always resulting in permanent damage to the retina. Yet microscopically there is evidence of collateral channels; the vein does not remain collapsed above the obstruction, but a blood-filled lumen is re-established by the accession of small vessels from the trabeculæ. A close analogy may be drawn between what occurs in the vein and what occurs in the artery. In each case on blocking, a collateral circulation is re-established, which however in almost all cases occurs too late and is insufficient in amount to restore function. In certain instances, however, as has been seen, some function *is* restored after complete blocking of the artery, and I have seen a case of typical thrombosis of the central vein in a young person in which all the hæmorrhages cleared up and the vision finally was 6/6.

The little hæmorrhages which are not infrequently seen near the disc somewhat late in obstruction cases are most probably the result of the giving way of capillary vessels under the strain of dilatation in the attempt to re-establish the collateral circulation.

There appears, therefore, to be a considerable body of evidence in favour of the occurrence of a collateral circulation when the main artery is blocked. This evidence may be briefly summarised as follows:—After an obstruction of the main stem of the central artery the vessels do not usually remain empty but refill, with or without some restoration of function. Such refilling is not well explained by flooding onward of the obstruction, or by incomplete blocking by it, or by relaxation of spasm induced by it, and it occurs too soon for canalisation of the plug to play a part. On the other hand the following points make the occurrence of a collateral circulation probable; the occasional preservation of some vision in an area bordering on the disc, the rare presence of visible fine collateral networks, and the not uncommon occurrence of small hæmorrhages in the same

situation, the refilling of the vessels after the division of the artery in the removal of tumours and in optico-ciliary neurotomy, and the analogy of what is known to occur in the veins. Unfortunately, in the present case, owing to the lapse of so long a time since the accident, little evidence can be adduced from the pathological examination. Secondary changes in the vessels, and atrophy of the nerve were much too advanced to allow of any judgment as to whether the collateral vessels had ever been enlarged. It may, however, be said that the block must have been complete and permanent from the first; yet there was visibly some circulation in the retinal vessels shortly after the onset of blindness, and microscopically they contained a little blood.

CASE 2.—This case presented itself as a branch obstruction, but the main interest centres in the conditions found in the main stem. I am indebted to Mr. Poulett Wells for the use of this case.

Clinical Notes.—A gentleman, æt. 65, had been complaining of gradual failure of sight in both eyes for some months. Early in October, 1904, the sight of the right eye suddenly became more defective, and he sought advice. The vision of the right eye was 6/24, the pupils active, the tension normal, and the media clear. On ophthalmoscopic examination the superior temporal artery was found to be narrowed, and the blood stream within it was interrupted and showed the characteristic breaking up of the blood column. The circulation in this branch of the artery was distinctly visible in its normal direction, and ceased altogether with the slightest pressure on the globe. The other branches of the retinal artery, beyond showing some thickening of the vessel wall, as evidenced by damming of the venous blood stream where crossed by the arteries, were normal. The veins were normal. Around the macula there were numerous small white retinal patches, and scattered throughout the fundus several small striate hæmorrhages. Examination of the field of vision showed an absolute sector shaped defect down and in, corresponding to the block in the superior temporal artery. In the left eye the vision was also reduced to 6/36, T_n, pupils active, media clear. Ophthalmoscopic examination showed retinal changes similar to the right, but rather more marked. The

arteries presented some sclerosis, but were otherwise normal; the veins were normal. The field of vision was full.

The urine was of high specific gravity, and contained much sugar but no albumen. The heart and lungs were normal.

On November 19th, 1904, sudden violent pain set in in the right eye with vomiting. The patient was seen two days later, when the right eye presented all the signs of an acute glaucoma, with T + 3, and no perception of light. The eye was therefore enucleated next day.

Pathological Examination.—The eye was preserved in formalin, bisected horizontally, and cut in serial sections. The nerve was excised and cut in transverse serial section from its intraocular surface backwards. The anterior chamber is deep, and there is coagulated exudate in the vitreous. The disc is cupped, and beneath it and to its nasal side there is a large exudative patch with a crystalline shimmer, and with hæmorrhage in and around it. Similar but smaller glittering patches are scattered about elsewhere.

Microscopic Examination.—The cornea is normal except for some slight vacuolation of the epithelium. In the anterior chamber there are fibrinous coagula, with a few blood corpuscles and leucocytes. The corneo-iridic angle is blocked, but to a very variable degree in different sections; the blocking is, however, always more pronounced on the nasal side. It is a true adhesion by new formed fibrous tissue, but there has not yet been much atrophy or condensation, and in some cases the extreme angle is free while the iris is adherent to the back of the cornea a little farther forward, a state of things which indicates that the adhesion is of recent origin. In no situation does the adhesion reach quite as far forward as the termination of the membrane of Descemet. The iris tissue generally is loose and uninfiltrated, but the vessels show thickening of their coats and proliferation of their endothelium, changes which in places cause obliteration of the lumen. Towards the root of the iris and also in the anterior part of the ciliary body there are considerable hæmorrhages; these are also present among the spaces of Fontana. The pigment epithelium shows very marked changes on the back of the iris. It is proliferated so as to be in many places several layers thick, while in others it rises into definite small papillæ. In addition, the individual cells are partially

depigmented, so that the dividing line between cell and cell has become more distinct, and it is along these divisions, and especially at the meeting points of several cells that the remaining pigment has become heaped up. The nuclei are often visible, and the dilatator is also seen, but the depigmentation is not sufficient to allow the details of its structure to be clearly made out. These changes cease quite abruptly at the junction of the iris with the ciliary body. Such appearances are well known in the eyes of diabetics; they were first described by Becker, and have been especially studied by Kamocki. There are also some little cysts between the two layers of the pigment epithelium near the root of the iris, and also in the pars plana near the ora serrata. The ciliary body and the choroid are normal.

Retinal and Central Vessels.—Many of the retinal vessels, both arteries and veins, are much diseased, while on the other hand others seem quite normal, and it is noticeable that normal and diseased vessels are often found in close proximity. The process has evidently affected the vessel in a very irregular manner. The smallest peripheral vessels are not infrequently entirely blocked, and sometimes show hyaline degeneration. In the larger vessels the process is clearly one of endothelial proliferation. The connective tissue wall of the vessel is traceable outside; and within it comes a layer of large blown-out cells with nuclei. These have narrowed the lumen in the eccentric manner which is characteristic of endarteritis (Pl. V, Fig. 2). In some cases the cells have a hyaline appearance, and the division between cell and cell is indistinct. In places these changes have caused complete obliteration of the vessel concerned, and this is notably the case with a main upward stem which is probably the one which was seen ophthalmoscopically to be blocked (Pl. V, Fig. 1). Other vessels, however, are markedly affected, which had not been noted ophthalmoscopically to be diseased. (Pl. V, Fig. 2.)

Following the arteries backwards, they show similar changes on the side of the cup, and towards the bottom of it form the main stem of the central artery. This is almost filled by large, ballooned, proliferating endothelial cells, with well defined cell walls. There are, however, a few red blood corpuscles among them, so that the lumen has not been entirely obliterated. The

artery here is much collapsed, but well within the lamina cribrosa this ceases to be the case. The artery suddenly regains its full size, but has its lumen almost completely blocked by endarteritis (Pl. IV, Fig. 1), only a very small cleft-like lumen being left at one side, which contains, however, a few red blood corpuscles. The cells composing this mass are of the same type as before, with large vacuolated bodies and fairly well stained nuclei. In the deepest layers there is a small calcareous nodule, showing the characteristic blue granular staining with hæmatoxylin. For about a quarter of the circumference of the vessel the mass in the lumen is intimately adherent to the wall, but there is no surrounding inflammatory reaction, nor any trace of organisation within it. In this position a small twig is given off from the artery which is also nearly blocked by endothelial proliferation. Staining with elastic tissue stains shows that all these changes are inside the membrane of Henle. The latter does not show its ordinary curly appearance, but is almost straightened out by the distension of the artery, there is no break in its continuity round the vessel. Following the artery backwards up the nerve the calcareous nodule increases in size, and has been ripped out of most of the sections. It also spoiled the edge of the knife, and in making the necessary readjustments after sharpening it again, a little piece of the nerve was unfortunately lost, so that the exact mode of termination of the nodule centrally cannot be described with certainty. It is, however, quite a localised nodule; a short distance above the lamina cribrosa the lumen of the vessel has again become free, of normal size, and blood-filled. The artery now remains perfectly normal for a space, without any thickening of its muscular coat or proliferation of its endothelium. (Pl. IV, Fig. 2.) Some distance up the nerve, however, endarteritis is again met with, narrowing the lumen very considerably in a characteristically eccentric manner. The appearances at this point differ, however, from those seen at the lamina cribrosa in one respect. Here there is considerable proliferation of the elastic tissue which forms the membrane of Henle, so that inside the true lamina there are numerous little curly fibres, as it were, little membranes of Henle. At the lamina, on the other hand, there is nothing of this, the process is purely one of endothelial proliferation, and among the proliferated cells there are no elastic

fibres. This difference, which I have observed in many other cases of endarteritis, is very striking and constant, and corresponds to a difference in the structure of the membrane itself in the two situations. As far as the lamina cribrosa the normal membrane of Henle is a true elastic membrane not resolvable into further details, but in the anterior part of the lamina and within it, it is broken up into a fine feltwork of elastic fibres. It appears that the reaction of the wall of the vessel to the cause of endarteritis is different in these two situations; above the lamina the elastic tissue of the membrane of Henle proliferates along with the endothelium, while within the lamina the elastic tissue fails to do so. Or possibly more correctly, it is the *subendothelial* tissue which proliferates chiefly above the lamina, and which is capable of laying down new membranes, while within the lamina it is the endothelium itself which proliferates, and is incapable of laying down new elastic tissue. At any rate, the fact remains that new formed elastic fibres are not found among the cells which narrow the lumen of retinal arteries in cases of vascular disease, whereas they are found among those which narrow the lumen of the central artery above the lamina.

To return from general questions to the present case however; in following the central vein backwards from the papilla, a single main stem is formed at about the same level as in the case of the artery. In the lamina cribrosa, however, where the obstruction occurs in the artery, this single lumen becomes divided into a number of loculi by connective tissue trabeculæ which traverse it. The vein has thus the appearance of cavernous tissue for a space, and it is difficult to say whether this is to be regarded merely as a peculiarity, or whether there has been a thrombus in it which has organised and canalised. There is no definite vein wall surrounding and enclosing all these loculi, and this favours the first supposition, but on the other hand when the vein has regained a single lumen, as it does some way up the nerve, this lumen is for a time very small and there is considerable round cell infiltration of the wall, facts which would favour the supposition that there had been inflammation and thrombosis (Pl. IV, Fig. 2). The question must be left unsettled. Farther up the nerve the vein receives several large tributaries and becomes of full size again

—much larger than the artery, in fact, which is here narrowed by endarteritis. These relations of artery to vein are preserved unchanged till the end of the series, which does not reach so far as the point of entrance of the vessels into the nerve.

Retina and Nerve.—The chief changes in the retina are found not far from the fovea, although the fovea itself is normal. They consist for the most part of large exudates between the two nuclear layers. These are found in groups in the neighbourhood of the macula, and scattered about irregularly elsewhere; they are either homogeneous or fibrillated, and many vacuoles are present in them. In addition there is œdema of the nerve fibre and ganglion cell layers, so that the limitans interna is raised up here and there in little vesicles. Some hæmorrhages are scattered about, but they are all small and situated in the inner retinal layers, not extending outwards beyond the inner nuclear layer. A few small cysts are present near the ora serrata, and in the same situation there has been a little in-wandering of pigment. The nerve fibre and ganglion cell layers seem to be a little atrophic everywhere, not only in the area supplied by the blocked vessel. The optic nerve is somewhat atrophic generally. No sector of atrophy corresponding to the affected sector of retina can be made out.

Briefly summarised, the pathological changes found in this case were as follows:—Hæmorrhages in the anterior chamber, iris stroma, anterior portion of the ciliary body, and spaces of Fontana. Moderate adhesion of the root of the iris to the back of the cornea without much condensation or atrophy. Vacuolation and loosening of the pigment epithelium strictly confined to the iris and not encroaching at all on the ciliary body. Hæmorrhages and exudative patches in the retina. Narrowing of the lumen of many of the retinal arteries by endothelial proliferation, amounting to complete blocking in the case of the superior temporal. In the main stem at the level of the lamina cribrosa, a localised nodule of endarteritis, almost filling the vessel but leaving a narrow lumen at one side. Farther up the nerve

the artery free for a space and then again much narrowed by endarteritis. The vein cavernous within the lamina cribrosa; farther up the nerve small and with round cell infiltration of its wall, then becoming normal again in size and appearance.

The retinal hæmorrhages and exudates and the advanced vascular disease are to be ascribed chiefly to the diabetes. The association of white patches and hæmorrhages with that disease is, of course, well known clinically, and the occurrence of arteriosclerosis has also been abundantly shown, both clinically and pathologically (Nettleship, Hummelscheim and Leber, etc.). The eye is not the only situation in which the connection is manifest, since arteriosclerosis is certainly a main factor in producing diabetic gangrene of the extremities. In the present instance the branch which actually caused the ophthalmoscopic picture of obstruction is shown in Pl. V, Fig. 1. It showed, as will be noted from the detailed description, neither embolism nor thrombosis, but only an advanced condition of endothelial proliferation which had resulted in its complete blocking. This endothelial proliferation, however, was by no means confined to the branch which had been visibly blocked, but affected to a less degree many of the other retinal arteries which had given very little sign clinically of being diseased.

In addition there was the large nodule in the central artery. It is evident that this must have been of very old standing, since a deposit of calcareous salts had occurred in its deeper layers. As it gradually increased it must have exercised an increasing effect on the intraocular circulation; indeed, one cannot but wonder, considering the little slit-like lumen which alone remains, that ophthalmoscopic evidence of its presence had not been produced long before. The circulation in the retinal arteries must have been greatly slowed, and it is easy to imagine that, since they also were affected with endarteritis, a time came when the deficient stream was unable to force its way through that

one of them which was the most markedly affected. It is unnecessary to call in the aid of thrombosis even, to account for the stoppage of the circulation, although obviously this might readily occur in vessels so diseased, and would produce the same consequences. It seemed not to be present anywhere in the present instance. The ophthalmoscopic appearance of branch obstruction would thus be produced, although the real seat of the mischief lay deeper—in the main stem of the artery.

The following case, although not subjected to pathological examination, may be quoted as being in all probability of the same kind as the foregoing. The patient was under the care of Mr. Treacher Collins, who has kindly permitted me to use it :—

P. S., æt. 52, a bargeman, attended the out-patient department of the R. L. O. Hospital on 16.xi.04, complaining of a slight mistiness before the right eye of five days' duration. V.R. 6/9 ; V.L. 6/6.

Ophthalmoscopic examination showed obstruction of an inframacular branch of the inferior temporal artery in the right eye. The artery was of normal calibre at its origin from the main stem, but a little distance out a faint opacity was seen upon or in it, and beyond this point it became very fine and thread-like. There was a roughly triangular area of retinal opacity corresponding to the distribution of the branch, and a corresponding area of the field of vision was lost—an incomplete sector not reaching to the periphery. Inhalations of amyl nitrite were without effect. The other arteries showed a moderate degree of arteriosclerosis. The fundus of the left eye was normal, except for slight disease of the arteries and banking of the veins where crossed by them.

The patient was a powerfully built apparently healthy man ; there were no cardiac murmurs, and no albumen or sugar was present in the urine. He gave a definite history of having acquired syphilis six months before, and was being treated for it at another hospital. There were some small ulcers on the inner side of his upper lip, some hard painless enlarged glands

in his groins, and a scaly eruption on his head and buttocks. All the palpable arteries were markedly rigid.

A month later he again presented himself with no new complaint. The vision was as before; the vessel formerly obstructed was still thin and thread-like, but the retinal haze had disappeared. There was, however, visible circulation in a small branch of the *superior* temporal artery. The junction of this branch with the main stem could not be traced, but a little bend or knee in the superior temporal indicated where it had come off. Following the artery outwards beyond this gap, there was first a space in which it was extremely small and reduced in places to a fine white line; it then suddenly swelled out, and contained a beaded column of dark venous-looking blood. Just at the spot where it enlarged a very minute branch was given off which at the first moment of examination seemed empty and was just distinguishable. The blood could not exactly be seen flowing in the beaded portion, but the clear areas between the beads altered in position slowly under observation, so that it was evident that some movement was going on in the current. While these vessels were being kept under observation, a dark bead of blood was seen to enter the almost invisible side branch. It very slowly pushed its way outwards, and after a little while lost its connection with the blood in its parent vessel, and slowly disappeared into the periphery, gradually thinning and lengthening as it went. Slight pressure on the globe totally emptied all these vessels, but on relaxing it again they soon refilled, and the same phenomena were repeated, a little more actively for a short time. The vessels on the disc pulsated on slight pressure. No change occurred during an hour or more while he was under observation.

One naturally thought that the circulation was just about to cease in this branch, but this proved not to be so, for on his next visit four days later it was quite re-established. The connection of the branch with the superior temporal artery could be easily seen; the part formerly venous was bright red again, and the little side branch was well filled. There was no beading or visible circulation anywhere.

He did not reappear again for nearly two months, when again his central vision was 6/9, but the ophthalmoscope revealed a

totally new set of phenomena. The main superior temporal artery for about one and a-half disc diameters was of normal diameter. It then suddenly became very thin, being converted into a white streak with just a trace of red in its centre. This lasted for about a disc diameter, and then the artery crossed a large branch of the superior temporal vein, and here there was a hazy white patch completely hiding it, and larger in diameter than the normal artery would have been. The vein was also completely hidden, and showed marked banking peripheral to the crossing. Beyond this the artery was of large size and very dark—quite as dark as the vein; the blood in it was beaded, and there was no movement at all in the current. Some of its smaller branches were also beaded and without visible circulation. Pressure caused the portion of the artery between the disc and the first constriction to disappear entirely, but had no effect whatever on the dark beaded portion. A sector of the field of vision was lost corresponding to the distribution of the superior temporal artery, and distinct from the area lost on the occasion of the first blocking. The left eye remained normal throughout. Since then the patient has not been seen again.

This is a case of retinal vascular obstruction in which the occurrence of true emboli seems to be out of the question. It is inconceivable that in a man without any demonstrable source for emboli these should have occurred and should have picked out three small vessels in one eye leaving the other eye quite intact. The only possible explanation must be found in a local disease of the arterial system of that one eye. It seems highly probable that this patient had in his right eye a condition similar to that found pathologically in Case 2 reported above, viz., a nodule of endarteritis on the central artery considerably interfering with the circulation in all his retinal branches. These retinal branches themselves were probably similarly diseased though not to a very high degree, since they showed but little change ophthalmoscopically. This, combined with the intraocular pressure, easily produced stoppage of the circulation in individual

branches, but the stoppage was in one instance, at least, capable of being overcome, probably by an improved state of the general circulation. It is very likely that he will some day have an obstruction of his central artery with total blindness, and in that case he will furnish an example of obstruction of the central artery with prodromal obscurations —not quite of the usual type it is true, since between the premonitory attacks vision has not been fully recovered and his fundus has not been normal, conditions which usually obtain in recorded cases with prodromal attacks.

Both these cases are, therefore, of interest with regard to the conditions precursory to the occurrence of total obstruction, and to the question of prodromal obscurations. It has long been considered a point against the diagnosis of true embolism if the patient gives a history of having had previous temporary obscurations of sight before the final attack of blindness, for it is evidently difficult to believe that large numbers of emboli could chance to enter the central artery, or that if they did the obscurations would be temporary and not permanent. More especially is this the case when one eye only is affected over a prolonged period. Nor does thrombosis offer a better solution of the problem, for there is no reason to think that thrombi could appear and disappear in the manner necessary. It is also difficult to believe that embolism is the correct explanation where both eyes are affected (Jessop, Olaf Page, Treacher Collins, etc.), and especially if this occurs simultaneously or nearly so (van Duyse, Knapp Loring, Haase, etc.). In many of these cases also there has been recovery in one eye but not in the other, which seems incompatible with both embolism and thrombosis. The objection seems to have been first stated by Loring, and both he and Nettleship have founded the argument upon it that in these cases there is probably local disease of the vessel wall rendering the retinal circulation liable to temporary interruption from comparatively slight causes—slight lowering of arterial pressure (in sleep for instance), venous stasis from exertion, bending, etc. Case 2

reported above may be looked upon as furnishing the pathological proof of such a supposition. It needs but a glance at Fig. 1, Pl. IV, to see how easily the retinal circulation might be cut off by some such slight cause, and how if this were speedily removed it might be restored again, but if not, how the block might well become permanent with or without thrombosis. Or even if it did not become permanent the retinal elements might be too much damaged to resume their functions when the circulation was restored. Two main factors probably go to the determination of these prodromal attacks, local arterial disease and diminished blood-pressure. In most cases the former of these two is of chief importance and the latter secondary. But in some cases this relation is reversed. Thus in a case of Priestley Smith's the obscurations were associated with fainting turns, due to the pain caused by vaginal douching for an ovaritis. One eye had already become permanently blind during one of these turns, and the douching being continued, repeated obscurations were occurring in the other, associated with faintings. On discontinuing the douchings and removing the offending ovaries both ceased permanently. In this case Priestley Smith's explanation is probably the correct one, that the obscurations were due to cardiac inhibition from the pain, with slowing of the cerebral and ocular circulations, while the permanent blindness of the left was caused by thrombosis of the central artery in that eye. Yet this association of obscurations with other signs of deficient circulation is distinctly exceptional in recorded cases, and it is probable that in most instances, as in the present one, the chief factor is local arterial disease, a cause which Priestley Smith also mentions in the same paper.*

The two cases reported above add to the large mass of

* The only case which I have been able to find in which the fundus was seen *during* one of these prodromal attacks is reported by Wagenmann, Arch. f. Ophth., vol. xliii, 1897, pt. 2, p. 219. He found that the vessels were small and thread-like, and did not pulsate as in ordinary obstruction cases, but quickly refilled with the return of vision. This case ended in an attack which did not pass off, permanent blindness resulting.

evidence already accumulated to show that of all parts of the ocular circulation the part in the immedate vicinity of the lamina cribrosa is that most liable to be affected by vascular disease in any form. This is undoubtedly the case with regard to the vein. In nine cases of thrombosis of the central vein examined by me in which the obstruction was found, it was situated in every one either within the lamina or just above it (central to it). With regard to obstruction of the central artery the fact is no less striking, and this is so whether the obstruction be a true embolus, endarteritis or endarteritis combined with thrombosis. The present cases illustrate the first two of these conditions. From the literature also the cases of Schweigger, Nettleship, Manz, and Marple furnish examples of true embolism in this situation; those of Galinowsky, and (probably) Nuel, Wagenmann, and Schnabel and Sachs' examples of endarteritis; that of Ridley (probably) of thrombosis. It is to be noted that this list includes all the best reported cases, and that in several of the others no obstruction at all was found (Hirschberg, Loring, Popp) probably because the lamina was not cut transversely, while in others again the descriptions are not satisfactory, and it is probable that secondary changes have been taken for primary. It will be evident on looking at Pl. III, Fig. 2, that the changes shown there could easily be taken for the primary obstruction, considering that the eye was obtained $3\frac{1}{2}$ years after the plugging. Indeed, this mistake was very nearly made in that case, for the calcareous mass had broken out of most of the sections and was all but overlooked. The case of Galinowsky is especially interesting, for it is almost exactly the same as Case 2 reported above. Just above the lamina there was a patch of marked endarteritis with a calcareous nodule in it. The case differed only in that the lumen was completely blocked, and clinically there was the picture of complete obstruction and not of branch obstruction as in the present instance.

What is the explanation of the fact that the lamina cribrosa is the seat of election for these various processes?

Many factors probably come into account and act in different degrees in different cases. In the first place the artery becomes narrowed as it passes through the lamina. In a normal eye excised for orbital tumour the central artery measured 145 μ at the lamina cribrosa, 166 μ a millimetre above it. This is a sufficient reason why emboli of a size to enter the central artery at all should become arrested at that point, but, in addition, it furnishes a cause for processes of endarteritis and thrombosis by increasing friction and causing eddies. Then again just beyond the lamina the current meets with increased resistance from two factors—the bifurcation of the main trunk, and the intraocular pressure. These reasons concern the artery alone, but in addition Haab has suggested that the ocular movements have something to do with the occurrence of vascular disease in this situation. The globe is to some extent anchored by the optic nerve, so that during its movements there may be a degree of pulling and dragging just where the nerve is inserted into the eyeball, although this is partly allowed for by the sinuosity of the nerve in its orbital course and by the fact that it is a little longer than the distance from foramen opticum to globe. This factor will act chiefly on the thin-walled and collapsible vein. It is possible also that the lamina cribrosa, which is chiefly composed of elastic tissue, exercises some elastic pressure on the vessels as they pass through it, and that the vessels are, therefore, less capable of compensatory dilatation in this situation. In addition it is certain that the connective tissue around the central vessels is more dense in the region of the lamina cribrosa than elsewhere—as if for protection of the vessels from some outside pressure. (See Pl. IV, Figs. 1 and 2.)

The next question which must engage attention is the connection, if any, between obstruction of the central artery and the subsequent occurrence of glaucoma. In the case of thrombosis of the central vein such a connection has been abundantly proved, and most of the pathological material has been obtained in consequence of this sequence of events.

With regard to obstruction of the artery, on the other hand, while several cases have been reported in which glaucoma followed, the connection is much less certain, and a large proportion of the eyes pathologically examined has been obtained from the *post-mortem* room. In all, glaucoma has been observed some 8 times. It followed within 4 days of the use of a mydriatic in one case (Ridley); a mydriatic had been used in two other cases (two by Nettleship), but whether it had anything to do with the onset of glaucoma or not is doubtful. In another case there were definite signs of iritis (Galinowsky); in Loring's case there were retinal and vitreous hæmorrhages. In a case of Knapp's, which presents many points of resemblance to Case 2 of this paper, the patient suffered from diabetes and an obstruction of the central artery occurred in one eye; later hæmorrhagic iridochoroiditis developed and glaucoma followed probably as a consequence. Thus there are left two (Manz, Marple), or counting Nettleship's 2 cases, 4 cases in which obstruction of the artery and glaucoma occurred in simple association. Is this number higher than might be accounted for by coincidence, or by the obstruction and the glaucoma being due to a common cause, arteriosclerosis, but not dependent the one on the other? In 1891 Fischer had collected over 150 cases of obstruction, and the number of *reported* cases cannot now number less than 200. This would give a percentage of 1 or 2, but in reality such a calculation is of no value whatever, for the clinical picture of obstruction is so well worked out now, that only cases presenting some new or peculiar feature are likely to be reported. On the other hand, cases complicated with glaucoma will probably be published both on account of the rarity of the combination, and because when it occurs it is not unlikely to lead to the obtaining of the eye for pathological examination. It is probable, therefore, that these 8 cases are all or nearly all that have occurred since the clinical characters of obstruction were well known, so that the condition must be one of great rarity—a supposition which accords well with clinical

experience. The combination with glaucoma has not been confined to one type of case; Nettleship's, Manz's and Marple's were probably true emboli, Ridley's thrombosis, and Galinowski's endarteritis.

It will be noted that in the present two cases glaucoma was present. But in the first it had evidently nothing to do with the embolus, but resulted entirely from changes in the anterior part of the eye. In the second case also it was probably not connected with the obstruction of the retinal arteries. There was much hæmorrhage in the root of the iris and among the spaces of Fontana, probably in consequence of vascular disease the result of diabetes, or from the abnormal constitution of the blood from the same cause. The glaucoma was therefore most probably to be referred to interference with the drainage channels. Knapp's case mentioned above is another example of the association of glaucoma with diabetes and hæmorrhagic iridochoroiditis. Hirschberg has also reported a case of glaucoma in a diabetic; it followed upon a hæmorrhagic retinitis. It is difficult to suggest any reason why glaucoma should be caused by a block on the central artery, for such a block will not give rise to any back pressure within the eye or damming back of lymph or blood. There will not probably be any alteration in the chemical constitution of the fluids in the vitreous or anterior chamber, and any explanation depending on changes in the characters of the fluids to be drained off is therefore improbable. In glaucoma following upon thrombosis of the central vein there are many obscure points, but at least there is obstruction of outflow, and some such alteration in the chemical characters of the fluids is conceivable. The evidence, therefore, does not seem at present to be sufficient to decide whether there is any true causal connection between obstruction of the central artery and glaucoma. On the whole the probabilities are against it, but the decision must be left to future research.

LITERATURE.

For convenience of comparison and reference, the cases of obstruction of the central artery which have been subjected to pathological examination have been briefly summarised and set down in tabular form. In order to economise space, the condition of the retina has not been mentioned, for in all the cases in which it has been described it has been the same, viz., atrophy of the nerve fibre and ganglion cell layers with preservation of the outer layers which receive their nourishment from the chorio-capillaris of the choroid. It has been asserted, with probability, on *a priori* grounds that the retinal haze seen soon after the occurrence of the obstruction is not due to œdema as is frequently assumed, but to parenchymatous degeneration or coagulation necrosis of the inner layers of the retina supplied by the central artery No case seems to have been examined early enough to prove this definitely, and œdema has certainly been found in later stages by several authors (Hirschberg, Nettleship, Nuel, Ridley, Manz). The present cases throw no light on the subject. There was indeed œdema of the retina in the second case, but it was clearly connected with the diabetes and not with the obstruction of the artery.

A few explanatory and critical remarks with regard to the cases on the list may be permitted. SCHWEIGGER'S is the case originally observed by v. Graefe on which the first description of "embolism of the central artery" was founded. From the picture given it seems to be a true case of embolism altogether similar to Case 1 reported above. SICHEL'S was not a typical case clinically—there was a large macular hæmorrhage—and the significance of the pathological lesion found is also doubtful. Most probably it was a nodule of endarteritis, possibly calcareous, and analogous to Case 2 and Galinowsky's case. In LORING'S case no obstruction was found, but it seems probable from the clinical history that one must have been present which was overlooked. The region of the lamina cribrosa was cut longitudinally, not

Author.	Sex and age.	Evidence of vascular or renal disease.	Clinical features.	Pathological examination.
1. SCHWEIGGER, Vorles. ü. d. Gebrauch des Augenspiegels, p. 138, and Pl. III, Fig. 10, 1864.	M., ?	Aortic stenosis and regurgitation.	Typical picture. Some vision for a time in temporal field. Eye obtained *post-mortem* 1½ years later.	Rounded mass just above lamina. No organisation or reaction in walls around. Artery filled with thrombus above. (Picture.)
2. SICHEL, Arch. de Physiol., vol. iv, p. 83, 1871.	F., 54	Mitral regurgitation. Died with aphasia, etc. No albuminuria.	Sudden loss of vision after a fright. Large hge. in macula and small hges. in periphery. Sclerosis of arteries on disc. Obtained *post-mortem* 14 months later.	In the artery from just behind the lamina for 9 mm. backwards, a mass of round, granular, globular bodies, filling the lumen, and tapering off in both directions. No vein present in the same situation. (Picture.)
3. LORING, Amer. Jl. Med. Sc., vol. lxvii, p. 313, 1874.	F., 62	No cardiac or renal disease. Died of apoplexy following upon phlegmasia dolens 1½ years later.	Retinal and vitreous hges. Cherry spot. Arteries not much reduced. Veins distended. *Glaucoma* 6 weeks later. Excision 2 months from onset.	*No obstruction found.* Central artery and vein nearly empty. Thrombi in choroidal veins. Lamina appeared to contain an excessive amount of fibres and round cells. (No picture.)
4. NETTLESHIP, R. L. O. H. Rep., vol. viii, p. 9, 1874.	M., 54	Aortic and mitral systolic bruits.	Typical picture. Small hges. near temporal side of disc. Some vision for a time in temporal field. *Glaucoma* 3 months later; iridectomy; excision 4 months from onset.	Mass in central artery extending from lamina into retinal arteries and ending in these with a blunt conical point. Probably organising; fibrinous and corpuscular structure, closely adherent to the intima. (Picture.)

5. PRIESTLEY SMITH, B. M. J., vol. i, p. 452, 1874.	M., 58	Aortic stenosis and regurgitation.	Typical picture. Irregularities in calibre of veins. Obtained *post-mortem* 4 months later.	Artery as a tube no longer in existence, but its position indicated by a circular mass of concentrically arranged fibrous tissue. (No picture.)
6. SCHMIDT-RIMPLER, Arch. f. Ophth., vol. xxii, pt. 2, p. 287, 1874.	?	Hypertrophy of heart and atheroma of aortic valves. R. hemiparesis 2 months before onset of blindness.	Blindness coming on during night. Exophthalmos and chemosis. Later, iritis and some retinal hges. Obtained *post-mortem* 10 months after onset.	Yellow mass mostly hyaline, completely filling lumen of artery some distance above lamina; a few nuclei in it and ? some vessels. Retinal vessels thickened, and some of them on papilla plugged. (Picture.)
7. NETTLESHIP and WATSON, R. L. O. H. Rep., vol. viii, p. 251, 1875.	F., 62	"Cardiac murmur."	Blindness with pain in head and limitation of movement of eyeball; no protrusion. *Glaucoma* 2 months later; iridectomy; enucleation 6 months from onset.	At lamina, and within it, artery contained a fibrous-looking material, mixed with molecular substance containing scattered corpuscles. Vein probably thrombosed. (Picture.)
8. GOWERS, Lancet, vol. ii, p. 794, 1875.	M., 30	Mitral systolic murmur and dilated heart. No albumen. R. hemiplegia proved *post-mortem* to be due to embolism of middle cerebral artery.	Typical picture L. discovered 5 days after onset of R. hemiplegia. Arteries larger in periphery than on disc. Obtained *post-mortem* 3 months later.	Many minute granular masses in central artery, largest $\frac{1}{8}$ inch above lamina. Similar masses in vessels on disc. (Picture.)

Author.	Sex and age.	Evidence of vascular or renal disease.	Clinical features.	Pathological examination.
9. Popp, Inaug. Diss. Regensburg (quoted in Manz), 1875.	F., 60	"Disease of the heart." Cerebral vessels calcareous.	Obtained *post-mortem* 3 years after onset of blindness.	*No obstruction found.* Retinal and central vessels normal.
10. Nettleship and Lawford, Trans. Ophth. Soc., vol. ii, p. 52, 1882.	M., 63	Heart normal. Glycosuria and albuminuria. Had been treated for "diabetes" when 18 years old.	Diabetic retinitis both, with picture of obstruction of central artery, L. Obstruction seemed to be visible on disc. Died of diabetic gangrene. Obtained *post-mortem.*	Artery thickened. Coats puckered, and lumen almost obliterated. No embolus found. Hyaline thickening of choroidal and some retinal vessels. Diabetic changes in retina, and great atrophy of nerve fibre layer. (No pictures.)
11. Hirschberg, Centralbl. f. prakt. Augenh., p. 1, 1884.	M., 45	Aortic stenosis and regurgitation. No albuminuria.	Typical picture. Prodromal obscurations 4 weeks before. Some small hges. at edge of disc. Obtained *post-mortem* 5½ months after onset.	*No obstruction found.* Retinal and central vessels normal. (Pictures.)
12. Schnabel and Sachs, Arch. f. Augenh., vol. xv, p. 11, 1885.	M., 33	Aortic stenosis and regurgitation. Mitral regurgitation. Slight albuminuria.	Typical picture L. 24 hours later arteries well filled, and showing beading and visible circulation in normal direction. 5 days later temporary obscu-	Obstruction at lamina partially occluding lumen, but with small blood-filled lumen at one side. Covered with endothelium. Similar structure in inferior main temporal artery, and other

			rations R.; recovered and remained normal till death 3 months later. Obtained *post-mortem.*	retinal arteries thickened. (No pictures.)
13. MANZ, Festschrift f. v. Helmholtz, p. 1, 1891.	F., 65	Aortic disease. Albuminuria.	Typical picture. V = fingers at ½ metre temporally only. Attacks of *glaucoma* 10 months and 1 year later. Death a little more than 1 year later. Obtained *post-mortem.*	Embolus at anterior part of lamina just at bifurcation of vessels; probably calcareous; no definite structure. Artery dilated and thrombosed farther up nerve; vein collapsed. A.C. deep. ∢'s blocked. Blood in root of iris and spaces of Fontana. (Picture.)
14. ELSCHNIG, Arch. f. Augenh., vol. xxiv, p. 65, 1892.	F., 50	Cardiac hypertrophy, sounds normal. Albuminuria. R. hemiplegia. *Post-mortem;* endarteritis of cerebral vessels and thrombosis of middle cerebral. Cardiac valves normal.	Typical picture L. discovered 4 days after onset of hemiplegia. Died 7 weeks later. Obtained *post-mortem.*	Obstruction in both main branches of central artery not completely blocking either. Lumen narrowed eccentrically and clothed with endothelium. Only slight endarteritis in central artery itself. (Pictures.)
15. WAGENMANN, Arch. f. Ophth., vol. xl, pt. 3, p. 221, 1894.	F., 45	Mitral insufficiency and stenosis. Granular kidneys.	Typical picture seen 5 days after blindness. A few small hges. near disc. Arteries remained very small, but pulsation returned. No p.l. at any time. Obtained *post-mortem* 12¼ months later.	Obstruction close behind lamina. Cellular mass with fine fibrils, fatty cells, cholestearin, and giant cells, leaving a minute endothelium-lined lumen partly at one side, partly within the mass. Much endothelial proliferation. Retinal arteries showed endothelial proliferation, and some were occluded. (Pictures.)

Author.	Sex and age.	Evidence of vascular or renal disease.	Clinical features.	Pathological examination.
16. MARPLE, New York Eye and Ear Inf. Rep., vol. iii, p. 1, 1895.	F., 56	?	Typical picture. Returned in 7 weeks with *glaucoma* apparently of some duration. Enucleated.	Embolus $\frac{1}{4}$ mm. by $\frac{1}{9}$ mm. immediately above lamina. Little structure, and probably calcareous; vessel dilated at this spot; contains corpuscles both in front of it and behind. Artery makes a sharp bend just peripheral to the obstruction. (Pictures.)
17. RIDLEY, R. L. O. H. Rep., vol. xiv, p. 264, 1895.	M., 57	Occasional cardiac irregularity; no murmurs; no albuminuria.	First seen 2 months after loss of vision. Vitreous opacity. All vessels much contracted except sup. temp. vein. H. and C. instilled for examination; eserin before he left. Returned in 4 days, having had pain since former visit. *Glaucoma.* Iridectomy and repeated paracentesis. Enucleation over 3 months from onset.	Mass of organised material in artery from cut end nearly to disc (3 mm.). Contains small vessels. Retinal arteries much thickened. A.C. ∢s blocked. Hge. in ciliary body. (Pictures.)
18. NUEL, Arch. d'Ophth., p. 166, 1896.	F., 53	"Diastolic murmur." Rigid arteries.	Typical picture L. V = hand-movements in part of temporal field; subsequently lost. Some small hges. Cyclitis (Tn.) and enucleation for pain 6 weeks from onset.	Organised mass with blood corpuscles among it at lamina. Organised tissue lifting up and growing under endothelium. Elastica traceable past mass. Artery dilated at situation of obstruction; dilated and empty above it;

				small and blood-filled below. Retinal arteries collapsed and thickened. (Pictures.)
19. SIEGRIST, 27ste Versamml. z. Heideberg, p. 10, 1898.	M., 47	?	Ligature of R. external, and later of R. internal, and common carotids in operating for carcinoma of tongue. On morning after second operation blindness R. Typical picture. Death 6 days later. Obtained *post-mortem*.	Thrombi in carotid, cerebral, and ophthalmic arteries, and in central artery before its entrance into nerve. None more peripherally. (Picture.)
20. MICHEL, Zeitsch. f. Augenh., pt. 2, p. 1, 1899.	M., 58	Widespread arterio-sclerosis. No albuminuria (but *post-mortem* chronic nephritis). Died of hemiplegia.	Typical picture with some hges. in periphery. Some improvement of vision later. Death 5 weeks from onset. Obtained *post-mortem*.	Endarteritis from lamina backwards for 6 mm. Flat and swollen hyaline cells and giant cells. In front of lamina just beyond point of greatest narrowing ($\frac{1}{16}$ of normal) a yellow homogeneous thrombus. Retinal arteries thickened. (Picture.)
21. WELT, Arch. f. Augenh., vol. xli, p. 355, 1900.	F., 34	*Post-mortem* thickened tricuspid. Thrombi in heart. Interstitial nephritis, etc.	Loss of vision after hæmatemesis. R. = fingers at 1 metre; L. = fingers at $1\frac{1}{2}$ metre. Picture of obstruction central artery, albuminuric retinitis and detachment of retina *both*. Detachments disappeared, and V. rose to R. 1/60, L. 1/24. Death 3 weeks from onset.	In R. central artery a thrombus a few days old. In L. central artery no thrombus, but a thrombus in the central *vein*. (Pictures.)

Author.	Sex and age.	Evidence of vascular or renal disease.	Clinical features.	Pathological examination.
22. GALINOWSKY, Arch. f. Augenh., vol. xliii, p. 183, 1901.	F., 74	Mitral and aortic first sounds impure. Peripheral arteries rigid. No albuminuria.	Blindness of L. 6 to 7 weeks before seen. Disc pale; arteries small. Slight iritis. Later *glaucoma*. Enucleation 2½ months from onset.	For 1 mm. above lamina marked endarteritis completely blocking and distending the vessel. Tapered off at the ends, leaving an eccentric lumen. Contained a calcareous nodule. Round cell infiltration of vein in same situation. (Pictures).
23. HOFMANN, Arch. f. Augenh., vol. xliv, p. 339, 1902.	M., 42	Chronic nephritis. Dilated heart.	Sudden blindness L. Typical picture. Later a few hges. R. Death 5 months later. Obtained *post-mortem*.	Organised obstruction 4 mm. long in L. central artery. Not intimately connected with wall. Similar condition in R. with a small blood-filled lumen at one side. (Pictures.)
24. GONIN, Arch. d'Ophth., p. 219, 1903.	F., 52	Mitral insufficiency. Albuminuria. R. hemiplegia 2 years before.	V. of L. lost during erysipelas. Retinal haze; arteries narrow; some striate hges. Vein rather dilated. Flat detachment below macula. Died 3 months later. Obtained *post-mortem*.	Granular mass penetrated by endothelial cells in central artery. Farther forward an organised canalised thrombus in the vein (of older date according to G.).

transversely. In NETTLESHIP'S first case there was undoubtedly an organising plug in the central artery, but whether an embolus or a thrombus it would be difficult to say from the pathological examination alone. The clinical history (aortic disease, sudden blindness without prodromata, etc.) makes an embolus more probable. His second case (NETTLESHIP and WATSON) is more doubtful, as he himself admits. His third case (NETTLESHIP and LAWFORD) seems to be one of endarteritis (? with thrombosis) the result of diabetes, and presents many points of resemblance to Case 2. The obstruction was found in the case of SCHMIDT-RIMPLER, but neither the description nor the picture enables one to come to any certain conclusion as to the nature of the lesion. There is no picture given of PRIESTLEY SMITH'S case, and the description is very brief, so that beyond the fact that the artery was occluded nothing certain can be affirmed. GOWERS states that the masses found by him in the central artery were probably not the original obstruction, since the vessel was collapsed above (proximal to) them. He believes that the true embolus had lodged at the origin of central artery from the ophthalmic, beyond the portion of nerve included in the sections. The association of the obstruction with emboli in the middle cerebral artery and in the kidneys and spleen, make it probable that it was a true embolus however. In POPP'S case nothing was found, and it must be supposed that the obstruction was overlooked (lamina cut longitudinally). It is impossible to believe with Elschnig that an embolus or thrombus can be absorbed and leave no trace. The same remarks apply to HIRSCHBERG'S case. The case of SCHNABEL and SACHS was most likely one of endarteritis—small peripheral lumen clothed with endothelium. No picture is given. MANZ'S case seems to be a typical true embolus closely similar to Schweigger's, Marple's, and Case 1. A very excellent picture will be found in this paper. In ELSCHNIG'S, the pictures clearly show that the lesions described as emboli are endarteritis. There is the typical eccentric endothelium lined lumen and thickening mainly confined to the inner

coat. WAGENMANN'S case is probably of the same nature, but not so certainly so. MARPLE'S is another case of typical embolus analogous to Case 1. In RIDLEY'S paper the picture is far from clear, but from the description it seems sufficiently probable that the lesion found was a thrombus—whether a secondary thrombus or the true cause of the symptoms must be doubtful. The lamina was cut longitudinally. In NUEL'S case the real obstruction seems to have been found. It is an organising mass, presumably a plastic embolus or thrombus. Cardiac disease was present. SIEGRIST'S was undoubtedly a case of thrombosis spreading from the carotid after ligature, but as before stated it belongs to a class different from all the others mentioned. MICHEL'S case is a typical one of endarteritis and thrombosis, much like Case 2 above and Galinowsky's case. WELT'S case is altogether anomalous, both clinically and pathologically. It does not belong to the embolism group, but to the group of cases of blindness following copious hæmorrhage. Leaving out of account the somewhat remarkable fact that detachments of the retina disappeared within a few days in *both* eyes, there remains the explanation of a blindness of some three weeks' duration by a thrombus at most a few days old. Still more remarkable is the statement that while the ophthalmoscopic picture was similar in the two eyes, the central artery was obstructed in one and the vein in the other. The pictures are not more convincing than the descriptions, and the case must be altogether rejected. GALINOWSKY'S case is an excellent example of a nodule of endarteritis in the region of the lamina, and is well illustrated. It bears a very close resemblance to Case 2, except that the obstruction was complete. The pictures given in HOFMANN'S paper show nothing but an artery cut obliquely. The similar condition found in the other eye—in which there were no signs of arterial obstruction—is thus easily explained. It is impossible to accept GONIN'S explanation of his case. He found a granular mass in the artery indeed, but believed it to be a thrombus secondary to a block on the vein. The consequences of

obstruction of the central vein are, however, well known, and bear no resemblance to those of obstruction of the artery. In the same paper GONIN gives a case of severe hæmorrhagic retinitis in which an obstruction was found in the artery. To accept these two cases would be to upset innumerable other authentic records, so that an error of observation must be supposed.

Certain other cases might be quoted from the literature which have a more or less direct bearing on the subject without being in all respects typical. Thus ROTHMUND and EVERSBUSCH state, without giving details, that in a case of "embolism of the central artery" the diagnosis was strengthened at the autopsy by the discovery of a thrombus in the right carotid, middle, cerebral, and ophthalmic arteries. Apparently there was no microscopic examination of the central artery. Again, a case of FRIEDMANN'S lends support to explanations depending upon endarteritis, or endarteritis with thrombosis. A man of 52, without any cardiac or renal lesion, but with rigid radials, became affected with obstruction of the right central artery. A year later he developed spastic paralysis, and 2½ years after this he died of apoplexy. The whole system of basal arteries, down to the smallest twigs, showed obliterative endarteritis, and although the central artery was not microscopically examined, it seems probable that the blindness was due to a similar condition in it probably associated with thrombosis.

The general result of the examination of the literature, therefore, would seem to be that ample proof has been furnished that obstruction of the central artery may be due to one of three causes: (1) embolus, (2) endarteritis alone, (3) endarteritis with thrombosis. Thrombosis without endarteritis probably only occurs in exceptional cases, as where the carotids have been ligatured. There is at present no pathological proof that the obstruction may be caused by hæmorrhage into the nerve or nerve sheath, or by spasm apart from endarteritis.

References.

The references to cases pathologically examined have already been given in the tabular list. The following is a list of the other papers mentioned in the text; it does not pretend to be a full bibliography of the subject:—

Becker. Zur Anatomie d. gesunden u. kranken Linse, p. 158, Wiesbaden, 1883. (On diabetic changes in the pigment epithelium.)

Collins, Treacher. Trans. Ophth. Soc., vol. xvii, p. 324, 1897.

Fischer. Ueber die Embolie d. Art. Centr. Ret., Leipsig, 1891.

v. Duyse. Arch. d'Ophth., vol. xxii, p. 93, 1902.

Friedmann. Deutsche Zeitsch. f. Nervenheilk., vol. xvi, p. 140, 1900.

Gonin. Arch. d'Ophth., p. 167, March, 1905.

v. Graefe. Arch. f. Ophth., vol. v, pt. 2, p. 136, 1859. (Original description of embolism of the central artery.)

Grüning. Arch. f. Augenh., vol. vi, p. 35, 1877. (Ophthalmoscopic results of division of the nerve.)

Haase. Arch. f. Augenh., vol. x, p. 245, 1868.

Haab. System of the Diseases of the Eye, Norris and Oliver, vol. iv, p. 498. (Good résumé of the whole subject.)

Hirschberg. Centralbl. f. prakt. Augenh., p. 70, 1884. (On breaking up of emboli.)

——— Centralbl. f. prakt. Augenh., p. 74, 1891. (On diabetes and glaucoma.)

Hummelscheim and Leber. Arch. f. Ophth., vol. lii, pt. 2, p. 336.

Jessop. Trans. Ophth. Soc., vol. xx, p. 98, 1900.

Kamocki. Arch. f. Augenh., vol. xvii, p. 247, 1887.

——— Arch. f. Augenh., vol. xxv, p. 209, 1892. (Diabetic changes in the pigment epithelium.)

Knapp. Arch. f. Augenh., vol. x, p. 99, 1881.

——— Arch. f. Ophth., vol. xiv, p. 245, 1868.

Lang. Trans. Ophth. Soc., vol. xix, p. 74, 1899.

Lawson. Trans. Ophth. Soc., vol. xviii, p. 148, 1898.

Loring. Amer. Journ. Med. Sciences, vol. lxvii, p. 313, 1874.

Nettleship. { Brit. Med. Journ., June 14, 1879 / R. L. O. H. Rep., vol. xi, p. 269, 1887 } (On prodromal obscurations.)

——— Festsch. f. v. Helmholtz, p. 7, 1891. (On visible collateral circulation.)

——— and Lawford. Trans. Ophth. Soc., vol. ii, p. 52, 1882. (On arterio-sclerosis in diabetes.)

Olaf Page. Amer. Journ. Med. Sciences, vol. lxvii, p. 126, 1874.

Priestley Smith. Ophth. Review, vol. iii, p. 1, 1884.

Reimar. Arch. f. Augenh., vol. xxxviii, p. 291, 1899.

Rothmund and Everbusch. Mittheil. aus. d. Univ. Augenanstalt z. München, p. 328, 1882.

SCHLODTMANN. Ueber d. Extirpation retrobulbärer Tumoren mit Erhaltung des Augäpfels, etc., Case 1. Halle, 1900.
SCHNABEL and SACHS. Arch. f. Augenh., vol. xv, p. 11, 1885.
SCHNELLER. Arch. f. Ophth., vol. viii, pt. 1, p. 271, 1861.
STORY. Trans. Ophth. Soc., vol. xix, p. 87, 1899.
WAGENMANN. Arch. f. Augenh., pt. 2, p. 219, 1897.

DESCRIPTION OF PLATES III, IV, AND V (FIGS. 1 AND 2).

PLATE III.

FIG. 1, × 120.—The central vessels within the lamina cribrosa in Case 1. The lumen of the central artery is occupied by a granular but otherwise structureless mass with a vitreous fracture. It fully distends the lumen, the little cleft at one side being probably artificial. The surrounding connective tissue is dense, but shows no sign of inflammatory reaction, and there has been no attempt at organisation, although the obstruction had occurred three years and two months before. The vein in this situation is in two divisions, both of which are almost or entirely blocked.

FIG. 2, × 120.—The central vessels farther up the nerve in the same case. The artery is to the left, and can be distinguished by the wavy contour in its walls, which represents the elastic membrane of Henle. It is entirely collapsed and obliterated by proliferation and adhesion of its endothelium. The vein is concentrically narrowed by thickening of its walls (not by endothelial proliferation), but a little slit-like lumen still remains lined by a single layer of endothelium. No blood corpuscles were found in it in any of the sections. The nerve is extremely atrophic.

PLATE IV.

FIG. 1, × 120.—The central vessels within the lamina cribrosa in Case 2. The central artery is to the left; its lumen is of about the normal diameter, but is almost filled up with a nodule of endarteritis. There is, however, a minute cleft-like lumen in about three-quarters of its circumference, and in this a few red blood corpuscles are visible. The nodule itself consists of blown-out pale cells, similar to those found in the retinal vessels, but with rather better marked cell divisions and more deeply stained nuclei. The dark granular mass in the substance of the nodule is a calcareous patch. For about one-fourth of the circumference the structure is intimately connected with the vessel wall, and over the rest of its surface it has an irregular lining of endothelium. A small branch is given off in this situation, which is completely blocked by endothelial proliferation. The lumen of the vein is encroached upon by fibrous tissue which, in the sections succeeding this higher up the nerve, formed definite trabeculæ dividing the lumen into a number of loculi.

FIG. 2, × 120.—The central vessels higher up the nerve in the same case. The artery is to the left. It is distended, full of blood, and shows no

endarteritis. The distension in this case, as compared with the extreme collapse in Case 1, is probably to be associated with the fact that the obstruction farther down the nerve was not complete. The lumen of the vein is here no longer divided into loculi or encroached upon by fibrous tissue, but it is very small, and there is some cellular infiltration of its walls. Comparison with Fig. 1 shows that the connective tissue surrounding the central vessels is denser at the lamina cribrosa than farther up the nerve (see p. 290).

PLATE V.

FIG. 1, × 160.—A retinal artery in Case 2. It is a superior main branch, and is probably the one seen ophthalmoscopically to be obstructed. The lumen is quite obliterated by a structure which seems to have been laid down in concentric layers from one side. It shows therefore a faint lamination, and there are a few badly stained nuclei. From the changes found in the other retinal arteries and in the central artery it is probable that the process was one of endothelial proliferation.

FIG. 2, × 160.—Another artery from the same case. This is an inferior branch, and ophthalmoscopically it was not obstructed, and showed only a moderate degree of sclerosis. The process is evidently the same as in Fig. 1, but the obliteration is not complete, a small blood-filled lumen remaining at one side. The eccentric narrowing of the lumen is highly characteristic of endothelial proliferation.

NOTE.

While these sheets were in the press a long and important paper on vascular disease of the central vessels has appeared, by Harms (Arch. f. Ophth., vol. lxi, part 1, p. 1, and part 2, p. 245). Two cases of obstruction of the central artery are given. In one there was complete obliteration within the lamina cribrosa by an organised thrombus; in the other there was great narrowing of the central artery by endarteritis, with complete obstruction of the superior, and advanced disease of the inferior, retinal arteries. It is impossible here to summarise his results, which in many points agree with mine, and I must therefore be content with referring to the paper.

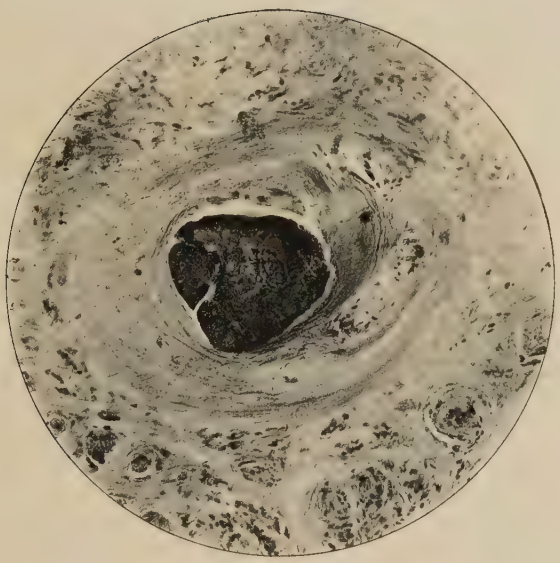

Fig. 1.



Fig. 2.

Bale & Danielsson, Ltd.

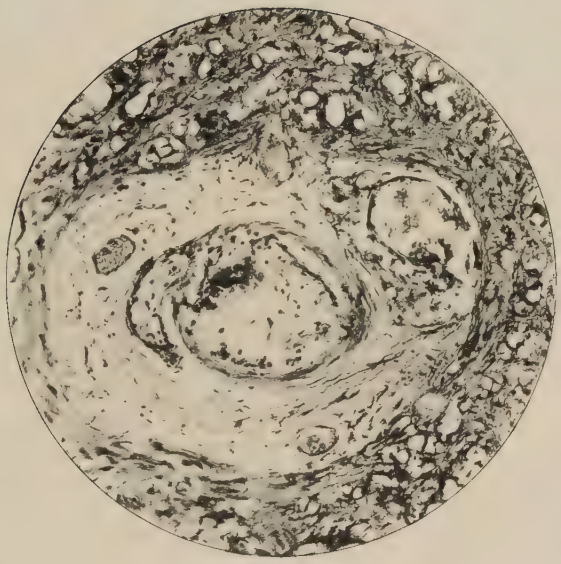

Fig. 1.

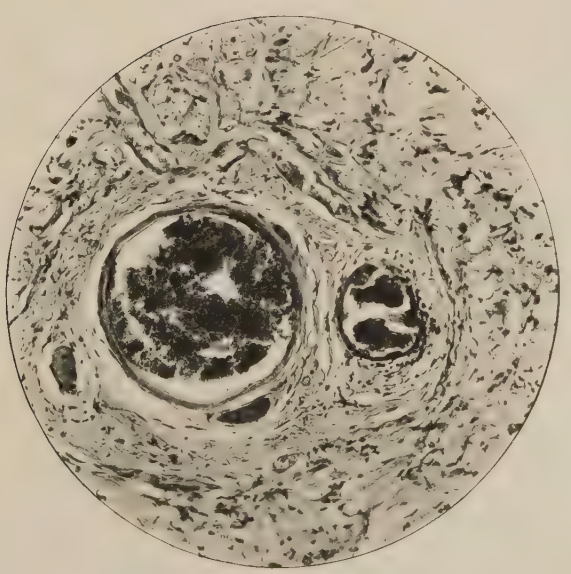

Fig. 2.

Bale & Danielsson, Ltd.



Fig. 1.

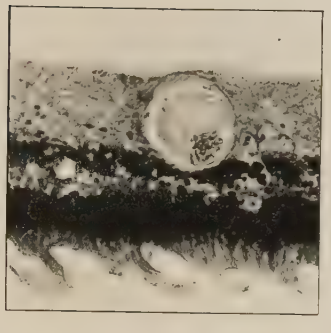

Fig. 2.

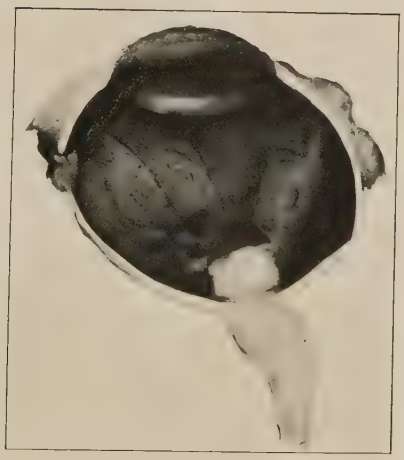

Fig. 3.

Bale & Danielsson, Ltd.

MARGINAL BLEPHARITIS: ITS CAUSE, PATHOLOGY, AND TREATMENT.

By Angus Macnab, M.B., F.R.C.S.

The application of bacteriology to the study of the inflammatory affections of the eye has signally failed in some instances to throw light upon the condition present. The same may be said of its application to general medicine. But as in the wider, so here in the more restricted field, its application has elucidated the cause of certain changes, and resulted in great improvement in our methods of treatment by giving us some indicator of progress more definite than mere clinical examination.

When we find a condition variously termed *Ulcerative Blepharitis, Marginal Blepharitis, Sycosis, Chronic Blepharitis, Tinea Tarsi, Tylosis,* without any cause being given for it, or any precedent condition out of which it arises, added to which the existence of many and contradictory methods of treatment, whose only common feature is their uncertainty, we may reasonably conclude that a bacteriological examination to determine the cause of this condition might also succeed in determining its treatment. Such a conclusion has been amply justified.

The bacteriological examination establishes the following facts:—

1. That the majority of cases of marginal blepharitis have the Morax-Axenfeld bacillus in their secretions.

2. This bacillus can be most readily obtained where the lesions are worst, *i.e.*, at the angle and the margins of the lids.

3. During the so-called cured condition, they are very difficult to find, and during relapses they are plentiful.

4. They exist at the onset of the condition, and still flourish after the disease has lasted for a life-time. In short, there is a very definite association of the Morax-Axenfeld bacillus with marginal blepharitis.

It is common knowledge that, amongst the various diseases of the conjunctiva, there is a well-marked type symptomati-

cally classified as "angular conjunctivitis." This has been proved to be due to infection with the Morax-Axenfeld bacillus, the proof even going so far as inoculation on the human subject. The infecting agent, incubation period, course, and treatment of this "angular" conjunctivitis are well known.

Here, then, are two conditions which, bacteriologically, show in common the presence of an organism of proved pathogenic properties in the human eye. The one has a definite onset, determined by inoculation, a course observed clinically, and a termination brought about by treatment. Untreated, it seems to lose its clinical entity, and pass into that chaos commonly known as chronic conjunctivitis. The other evolves itself out of the chaos, is vaguely recognised as a type, is profusely named, and occasionally cured. Its cause is not known; it is vaguely supposed to follow on a conjunctivitis; because it must follow something, and that is the most likely.

The relation between these two conditions is that they are stages of one and the same disease—"chronic blepharo-conjunctivitis." Every possible intermediate gradation between the extremes can be found, and when tested with the indicator which the microscope gives us, will show the proof of their identity, *i.e.*, the presence of the Morax-Axenfeld bacillus. They should therefore no longer be described separately, and classified as two distinct diseases.

This disease, "blepharo-conjunctivitis," has a very definite clinical history; its pathology and bacteriology can be determined, certain complications may occur during its course, and it responds rapidly to proper treatment.

The early stages are well known, and only a short *résumé* of the main facts regarding them will be given here.

The infection is probably through close contact, as in the cases of family and school epidemics, or through infected dust blowing into the eye, the organism having great resistance to dryness. After a latent period of about 36 hours there is an itchiness at the lid margins, with a dry or gritty sensation in the conjunctiva. In the morning the lids are heavy and stick

together. A glutinous white secretion collects at the outer and inner angles of the palpebral fissure, especially at the inner, and on the caruncle, which is red and slightly swollen. Several days later the margins of the lids redden. The normal smooth, shining, clean surface between the outer and inner lid borders changes progressively from the angles towards the centre. It becomes dull, sticky, moist, and deep red in colour. Along the roots of the cilia a whitish, glutinous secretion collects, and gums them together into tufts. The skin of the lids immediately outside the angles is red and moist; further out it is coated with the dried secretions. The cornea is not affected. The bulbar conjunctiva usually shows a light injection, not, however, affecting the circumcorneal region. At this stage each eye presents the appearance of being surrounded by two intensely-red V's lying on their sides with their apices directed away from each other; this is produced by the contrast of the red intermarginal lid border against the white sclerotic. The caruncle is now intensely injected and covered with secretion. When the lids are everted the conjunctiva is seen to be very little affected; there is often a slight velvety thickening on the lower lid, but this is always less marked at the fornix than near the lid border.

Usually a day or two after the onset in one eye, the other is attacked in an exactly similar way; and subsequent stages in the disease are therefore bilateral.

After three or four weeks the diffuse, intense redness of the intermarginal surface changes; the epithelium has been macerated and cast off; dull red blotches, at first very small, but afterwards increasing in size, appear near the roots of the cilia; these form definite excoriations, from which comes a serous exudation. Crusts form on the cilia and at their roots. If these are removed the red excoriations show beneath. Sometimes the conjunctival discharge is very free, and bordering on the lid margins is a skin region, moist, macerated, excoriated, intensely injected, and covered with a thin, whitish secretion. The subjective phenomena, burning,

itching, and pain, are well marked, and sometimes there is considerable photophobia. The part taken by the conjunctiva of the lids is much greater. It is quite thick and velvety, being even thrown into folds. The bulbar portion is injected, and sometimes even a little chemotic. These acute conditions are rare, and may be due to mixed infections.

Let this condition persist for years, and in a considerable number of the cases an ulcerative marginal blepharitis will develop, which is extremely chronic in type, and under the usual treatment of yellow oxide, massage, etc., may last for years—in fact, often recurring at intervals for the rest of the patient's life.

The changes are almost entirely confined to the free border of the lids and the skin adjoining. In health the free border of the lid presents an inner, or posterior, rectangular, sharp margin, which is adapted accurately to the globe, and, when the eye is shut, to its fellow opposite. The corresponding outer or anterior margin is also sharply cut, and forms an angle slightly acute, along which project the cilia. Between these two margins lies the smooth, flat, shining intermarginal portion, marked by a line of round lighter coloured spots—the mouths of the ducts of the Meibomian glands—parallel to the root sheaths, and rather nearer the posterior edge. The adjoining skin is loose, very soft and pliable, and slightly redundant.

The inner lid margin adheres to the globe by surface tension, the intermarginal portion being continuously oiled, remains dry, and there is no tendency to epiphira.

Contrasted with this, in marginal blepharitis we have the presence of ulceration, the destruction of this beautifully-moulded lid margin, the loss of many cilia, and changes in the adjoining skin and conjunctiva.

The process of excoriation of the epithelium progresses after the underlying corium is exposed until the inner and outer lid margins, along with the intermarginal area, have been destroyed by ulceration. Temporary healing takes place at parts, where we see an irregular rounded border, not

accurately adapted to the globe, showing a few scattered Meibomian duct orifices and irregularly-placed hair follicles.

At other parts are thick crusts, through which tufts of cilia protrude, and scabs which cover up the destruction which is going on. Some of the hair follicles become infected with pus forming organisms (Staphylococcus usually), so that we see occasionally a small abscess from which a hair projects. Where temporary healing has occurred, the newly-formed skin again becomes macerated and the process repeats itself anew. Throughout there is a definite tendency for the canthi to be more affected than the mesial portion. Occasionally the canaliculi become closed, but this is uncommon.

This continual contraction of the scars along the margin of the lids causes a degree of blepharo-phimosis, which mostly affects the outer angle. The skin, especially of the lower lid, being drawn upon and continuously absorbed in the ulcerative process, loses its pliancy, is shortened and thickened, producing an ectropion usually of very slight degree, and a difficulty in closing the lids. The upper lid is thickened near its margin, so that it has a heavy rolled-up appearance, the skin is smooth, dense, and reddened, around the canthi we can always see the moist, macerated area on which the gummy whitish secretion collects, which was so typical of the early stages.

In cases where the ulceration is rapid, the conjunctiva is everted, turning out to the lid margin, and forming a deep red, smooth, shining line between the white sclera and the crusts, which mark the true lid border.

In the extremely slow and chronic cases, which may have lasted without very much destruction for 20 or 30 years, it is more common to find some entropion and trichiasis, especially of the upper lid.

A marked feature is the deficient power of closing the lids; this should be completely done without contraction of the frontal portion of the orbicularis palpebrarum, but in some of these patients when they are told to gently close their eyes, about 2 to 3 mm. of sclerotic remain

visible below the upturned cornea. This is only covered by contraction of the whole orbicularis, when the skin is wrinkled by the strain put upon it.

Many of these patients have their canaliculi slit up and their nasal ducts probed; this being repeatedly done adds a nasal duct stricture to their blepharitis, and changes the case from a simple one amenable to treatment to an extremely intractable form of lachrymal stenosis.

Although ulcerative marginal blepharitis is quite common, yet considering the enormous frequency of diplobacillary conjunctivitis, it is obvious that only a limited proportion of the cases reach this stage. The angular conjunctivitis stage remains often for many years. In some cases the lid condition is very slight, but the patients seem to develop very readily ulceration of the cornea. These ulcers are usually called "catarrhal"; they are shallow, oval, or round, with faintly infiltrated base, and readily heal, leaving a small facet. Occasionally a little hypopyon is found, and rarely does the ulcer penetrate deeply with a tendency to perforation. Unsuitably treated, these are very chronic, patients have informed me that they have had "scores of ulcers"; but if the condition be correctly diagnosed, and the treatment directed to the conjunctiva, a good result can easily be obtained.

Pathological Changes.—The chief changes take place in the epithelial layers of the lid margins, but there are also some in the deeper parts, the tarsal plate itself being affected. The epithelial changes occur mostly at the lid margin; here in the intermarginal portion there is an increase in the squamous, keratinized elements of this transitional epithelium, making it more resemble skin. The deeper layers of cells have proliferated, and sent processes down into the corium, so that the epithelial coat varies very greatly in thickness; at some places, that is, opposite these processes, it is very thick; at others, between them, it is reduced to one or two cells in thickness, and where thus reduced we find the subjacent corium densely infiltrated by small cells. These places correspond to the macerated red patches observed clinically. The

thinning may go on to such an extent that the corium is actually exposed, and then we have an ulcer formed, which increases in size by confluence of such exposed spots. Such ulcers, however, remain quite shallow, and their bases contain the processes of epithelium as small islets of cells which have a continuous tendency to spread out and re-cover the denuded surface.

In the granulation tissue formed by vascularization of the small-celled infiltrate there is a continuous contraction going on, dragging on the internal or posterior lid border, thus narrowing the lid margin, and causing slight ectropion of the conjunctiva.

Where such ulcers have healed the lid is covered by several layers of a stratified squamous epithelium, under which is a non-vascular cicatricial fibrous tissue.

The root-sheaths of the cilia are atrophied, and surrounded by a small-celled infiltration; they are very much reduced in numbers, and some are altered in direction.

The Meibomian glands are dilated, some cystic, their ducts are often obliterated by the ulcerative process, those remaining open irregularly.

The inner lid margin cannot usually be defined; at the limit of the conjunctiva there is a thickening of the epithelium to form many layers of cells, here the surface falls away from the bulb, and the area of ulceration begins. This rounded irregular line corresponds to the situation of the inner lid border.

In the conjunctiva there is a marked increase in the number of goblet cells, and the epithelium rests upon a densely infiltrated layer of the corium, especially towards the lid margin; these changes diminish as we pass to the formix, where the conjunctiva is almost normal.

The bulbar conjunctiva is normal; in fact, any change which may exist here is related to some coexisting or previous conjunctivitis.

The tarsal plate shows changes throughout in the lower lid, and at its lower margin in the upper; there is an infil-

tration with small round cells, and fibrous tissue formation, causing thickening and distortion, usually a slight entropion of the upper plate, and ectropion of the lower.

The lids, both upper and lower, are distinctly shorter than normal.

Bacteriology of the Condition.—The only constant, and in the writer's experience almost invariable organism found in these cases is the diplobacillus of Morax and Axenfeld. It is found in the gummy secretion collecting about the angles, in the crusts at the roots of the hairs, and in the moistened scabs which cover the ulcers. In the old confirmed cases it naturally can rarely be obtained in pure culture. But its constant presence, and the gradual evolution clinically of the ulcerative stage of the disease, from a slight "angular conjunctivitis," which is certainly due to a pure infection with this organism, make its causal connection with the disease absolutely certain.

The organism itself when in young culture, or from a recent case of blepharo-conjunctivitis, has the following morphological characters. The bacillary form is constant. The rods are from 1·5 μ to 3 μ in length, and 0·5 μ to 1 μ in breadth. They are quite straight and even in calibre, the ends being slightly rounded. They lie end to end in pairs, these pairs may form chains; single rods are also occasionally seen.

The protoplasm shows a tendency to stain more deeply at the ends of the rods than in the middle. Capsules are readily seen by special staining, and sometimes even in a methylene blue preparation. The bacillus is gram-negative, and can only be confused with that variation, which has been given a special name, *B. liquefaciens*, by Petit.

The form is very constant in smear preparations from recent cases, or in young cultures. From old blepharitis cases, while some of the organisms are of this typical shape, others vary from it so much as to be almost unrecognisable. Large single round or oval bodies, more refractile than the small ones, are not uncommon. Double cocci, kidney shaped, with their concavities together, and of 2—3 μ in diameter, are

more common. Tetrad groups, and perfectly round bodies in short chains of paired individuals, also occur. These are all of large size and gram-negative, although not so easily decolourised as is the small rod form.

That these grotesque shapes are really vagaries of the diplobacillus is certain, as all grades in shape between them can be found; and if a culture be taken from a case of long standing blepharo-conjunctivitis, the pure colonies isolated, and reproduced on fresh medium, the transition is very clearly seen. After about 4 or 6 hours' growth, from the large oval bacillus a short chain is formed, the centre of which is formed by two oval bodies, several times the thickness and length of the ordinary organism; at each end of the chain is a pair of typical diplobacilli, and the different intermediate stages are seen between. Where a large round "spore" has broken up we find very regular rosettes, the centre formed of two or three round bodies from which radiate out lines terminating in typical diplo-forms. In these colonies the parent has broken up at first by irregular cleavage planes, but later by transverse division. The same culture in 24 hours will have lost most of the irregular forms; and in 48 the smears show typical diplobacilli with occasional oval hefa-like bodies distributed through them.

To obtain a specimen showing the typical form without any of these variations, it is best to grow the bacillus on agar with ascitic fluid added; the growth is rapid, and if second and third sub-cultures are made each 24 hours old, the type will be found practically constant.

From the conjunctiva direct, the typical form is obtained in great numbers from cases of early angular conjunctivitis of about a week's duration, especially when it is the first attack, and where there is much secretion. The large forms are readily obtained in old standing blepharitis, and in recurrent attacks of angular conjunctivitis in the early stage. In fact, their presence indicates the chronicity of the case; the writer has found that it is quite feasible to give an opinion from the appearance of the secretion-preparation, as

to whether the case is an old one or a recent infection, and thus control patients' statements as to the duration of the disease, and the existence of previous attacks.

The diplobacillus grows on a limited range of media. On Löffler's blood serum and ascites agar it can be grown with certainty. In pepton broth a very slight growth, and on the other commonly used media not containing blood or human serous fluids no growth is obtained. That variety described by Petit, and further examined by the present writer, shows, in general, a more vigorous growth, and also the additional power of growing on pure agar, in other respects it has no essential difference.

Ascites Agar Growth.—Single colonies grow superficially, in a stroke culture, as transparent drops, which afterwards become grey and more opaque. These coalesce and form a greyish slime, which looks brownish in transmitted light. In from 3—8 days at 37° C. the growth reaches the sides of the tube, and later a brown discoloration spreads into the medium.

On blood serum (Löffler) at 36° C. In 12 hours, when the culture is made from a fresh case, single colonies are seen in the form of clear, transparent moist spots, slightly excavating the surface. These begin to coalesce in about 24 hours, and the liquified medium runs down to the bottom of the tube, leaving hollows and furrows on the surface, which when examined by transmitted light show brownish coloured bases. The medium takes on a brown discoloration, which deepens with age. The ordinary type of diplobacillus often dies out when repeatedly transferred from one serum tube to another, the Petit type is more resistant and can be cultivated on this medium for an indefinite time.

The resistence of the organism against heat is very low, after 5 minutes on a water bath at 55° C. the culture is killed. Dryness, on the contrary, has very little effect on the organism, after 14 days' drying at 37° C. they retain their vitality.

Treatment.—The researches of Morax and Axenfeld have shown the great value of the use of sulphate of zinc in the

treatment of angular conjunctivitis. A collyrium of 2 grs. per ℥i is dropped into the conjunctival sac three times a day until the organisms disappear from the secretion, when the strength can be reduced to 1 gr. per ℥i.

The greatest benefit is obtained in the late stages of the disease, when there is ulcerative blepharitis, by the same treatment. A preliminary cleaning of the lids from crusts and scabs, by the use of a warm bicarbonate of soda lotion and careful wiping along the edges, allows the zinc better access to the organisms. An ointment of oxide of zinc 20 grs. per ℥i should be ordered to be applied along the lid margins at night. With this treatment the ulceration of the lids rapidly disappears, and the organisms are no longer found in the secretions. The strength of the zinc drops can now be reduced to 1 gr. per ℥i, which is, of course, much less irritating. If there is much associated thickening of the conjunctiva, an occasional painting with silver nitrate, 10 grs. per ℥i, and careful neutralisation with saline, is very useful.

When the active changes have ceased, massage with a diluted yellow oxide of mercury ointment, 4 grs. per ℥i, will assist in diminishing the thickening of the lid margins.

Ectropion of the punctum, blepharo-phimosis, entropion, and trichiasis may need surgical treatment on the ordinary lines for such affections.

The tendency to recurrence is very great. Treatment must be kept up for at least one month after all active changes have disappeared.

Conclusion.

A large proportion of the cases, clinically termed ulcerative marginal blepharitis, belong really to the disease called blepharo-conjunctivitis or diplobacillary conjunctivitis. They can be fairly accurately distinguished clinically; and microscopically with certainty. Their cause is an infection with the Morax-Axenfeld diplobacillus. The disease is not self-limited, and spontaneous cure is rare.

The treatment by the use of sulphate of zinc gives the best results.

ON IMPLANTATION DERMOIDS OF THE CONJUNCTIVA.

By M. S. Mayou.

So little has been written on the subject of Implantation Dermoids of the Conjunctiva that Cirincione[1] goes so far as to doubt that they occur. So far as the literature of the subject goes there are cases on record by Uhthoff[2] and E. T. Collins.[3]

Implantation Dermoids of the Conjunctiva arise in two distinct ways:—

(*a*) By the down growth of the surface epithelium of the conjunctiva following a wound of that membrane, the connection with the surface epithelium becoming subsequently cut off by atrophy, due to pressure of the newly formed fibrous tissue. That this method of formation no doubt occurs not infrequently, I have shown elsewhere.[4]

(*b*) Direct carrying in of the conjunctival epithelium by a foreign body. That this method of formation does occur has not been previously proved, as in the two cases mentioned above the cysts were not cut in serial section, so that positive evidence that there was no connection with the surface epithelium was wanting, and the length of time existing between the injury and the examination of the specimens may have caused its disappearance if present. I had the opportunity of examining a case one week after the bulbar conjunctiva was injured by a chip of wood striking it.

F. M., male, æt. 11.—On November 2nd, 1902, five days before being seen, the patient was breaking a piece of wood, and a piece flew up and struck him in the right eye. It pained him at the time, but he did not take much notice of it until two days later a "blister," as his mother described it, appeared on the outer part of the right eye.

On admission there was a red swelling, having the appearance of a large phlyctenule, on the outer part of the bulbar conjunctiva in the palpebral aperture, about 6 mm. from the limbus. There was no photophobia and the conjunctival injection was more or less limited to the area surrounding the swelling. No foreign body could be seen. As its nature was doubtful, it was excised. It was not adherent to the underlying sclera. A stitch was put in and the wound healed by first intention.

The specimen was hardened in alcohol and serial sections made, stained with logwood and eosin and by Pappenheim's method. The wound on the surface had not become completely covered with epithelium, but beneath the gap in the epithelium there was new fibrous tissue. The position of the cyst with regard to the entrance wound was somewhat oblique, the piece of wood having evidently passed obliquely beneath the surface epithelium. Inside, the cyst contained the splinter of wood causing the injury, as well as many mononuclear and polynuclear cells of all types, a few degenerated plasma cells, and one or two giant cells. The epithelium lining the cyst was for the most part three or four cells in thickness, of the type found on the surface of the bulbar conjunctiva; it surrounded the wood with the exception of a small area opposite to the entrance wound, the epithelium having evidently been carried in in front of the splinter, and then grown round it, as there was evidence of recent mitosis having occurred in the cells at the ununited ends. No process of epithelium could be found in any of the sections connecting the surface epithelium with that of the cyst. Around the cyst there were numerous new and dilated vessels which showed enormous proliferation of their endothelium, with very active diapedesis taking place. The tissue also around the cyst contained numerous leucocytes, plasma cells, and giant cells. The exudation was situated around the vessels, many of these vessels having both endothelial and perithelial coats and some intermediate tissue; in fact, their walls were of such thickness that it is impossible to believe that cells having so little amæboid movement as lymphocytes and plasma cells can have made their way through them.

Another curious point was that some polymorphonuclear and

even some of the mononuclear cells were stained a brown colour. These cells were lying side by side with normally staining cells. They were found in greatest numbers near the chip of wood, to which their brown colour was evidently due, but they were also found in the vessels in the neighbourhood of the wound. If this was due to the ingestion of some material (? tannin) from the wood *ante-mortem*, some of the polynuclear cells must have made their way back into the vessels, which is against the generally accepted view. But much stress cannot be laid on this as it is possible that it may have been produced *post-mortem*, although the general appearance did not suggest it, since these brown cells lay side by side with normal staining cells.

Conclusions.—The fact that there was no process of epithelium connecting the surface epithelium with the epithelial cyst wall, and that the cyst wall was even deficient towards the surface wound in an implantation cyst of such an early date as this, disproves the theory that all these implantation dermoids are due to down growth of epithelium from the surface, and although the other form of implantation dermoid does undoubtedly occur, carrying in of the epithelium also takes place.

CASE 2.—The mode of formation in this case is much more indefinite than in the case previously described, but shows well the subsequent changes in the epithelium.

C. S., male, æt. 40.—Seen September 4th, 1903. Came to the hospital complaining of a small swelling on the outer side of the bulbar conjunctiva of the left eye. Strong, healthy man. Had at different times received injuries from foreign bodies striking the eye.

On the outer side of the left eye was a semi-transparent swelling about the size of a large pea, evidently containing fluid, with no injection around. He had noticed the swelling two months before, and it had gradually increased in size. The cyst was removed entire, and the wound closed by stitches. Primary union followed.

The specimen was hardened in alcohol, embedded in paraffin and cut in series. The epithelium of the bulbar conjunctiva

covering the cyst was similar to the surrounding epithelium, except that the cells on the surface were more flattened. Between the cyst wall and the surface epithelium was a layer of connective tissue containing blood vessels, a few lymphocytes, and a considerable number of mast cells. No process of epithelium was found connecting the epithelium of the cyst with the epithelium of the bulbar conjunctiva. The cyst itself consisted of an outer wall of slightly thickened connective tissue and was lined by epithelium throughout its whole extent. It varied considerably in thickness from four or five cells up to ten or twelve.

The cells were not flattened but rather of a columnar shape. Tuft-like processes were present in which the columnar shape of the cells was still more marked. Scattered amongst these columnar cells were round and oval cells which were most apparent towards the free margin of the tufts. These cells were clear and non staining, and were evidently epithelial cells undergoing mucoid changes, probably supplying the interior of the cyst with the fluid with which it was filled.

References.

(1.) Cirincione. Deutschmann's Beiträge zur Augenheilkunde, part lv, 1903.
(2.) Uhthoff. Berlin. klin. Woch., 1879.
(3.) E. T. Collins. Researches, 1896.
(4.) Mayou. Hunterian Lectures, 1905.

Description of Fig. 1 and Plate VI.

Fig. 1.—Section through the entire implantation dermoid (Case 1):—

A. Epithelium.
B. Wound through which the piece of wood entered.
C. The epithelium lining the cyst.
D. Piece of wound surrounded by leucocytes.
E. Newly formed vessel in the neighbourhood of the cyst.

Plate VI.

Fig. 2.—Epithelium (Point C, Fig. 1) lining the cyst cavity; many of the cells have two nuclei, and there is evidence of recent mitosis having occurred in some of the cells:—

F. Giant cell in the neighbourhood of the cyst wall.
G. Epithelial cells on the inner side of the cyst wall.

FIG. 3.—A portion of the wood in the interior of the cyst :—

H. Wood.

I. Giant cell.

I′. Polymorphonuclear leucocytes, the staining reaction of some of which is altered by the presence of the wood, I″.

J. Mononuclear leucocytes, do. do. do.

FIG. 4.—A vessel (marked E, Fig. 1) :—

K. Endothelial lining to vessel.

L. Polymorphonuclear leucocytes, some of which are altered in their staining reaction similarly to those found around the wood, L′.

M. Mitosis in a perithelial cell.

$\frac{1}{12}$-in. obj., No. 8 eye-piece.

FIG. 5.—Cyst of the ocular conjunctiva (Case 2) :—

A. Surface epithelium.

B. Connective tissue wall.

C. Epithelial lining which has proliferated into tuft-like processes.

D. Cells undergoing mucoid changes (stains—logwood and Van Gieson).

$\frac{1}{12}$-in. oil immersion, No. 4 eye-piece.

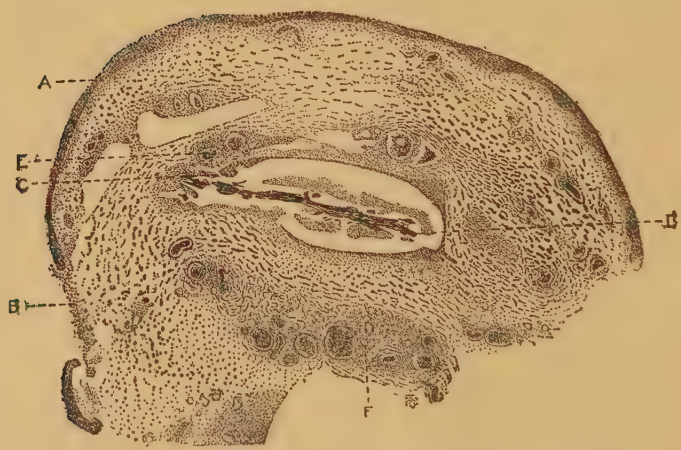

FIG. 1.

Fig 2.

Fig. 3

Fig. 4

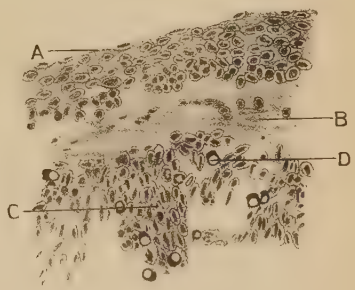

Fig. 5

Bale & Danielsson Ltd. lith

GLIOMA RETINÆ.*

By S. A. Owen.

Since the appearance of the last article upon this subject by Mr. Marshall (in the Ophthalmic Hospital Reports, vol. xiv), 24 cases of glioma retinæ have occurred in the practice of the hospital. These 24 cases represent 26 eyes. In addition to these a record is given of 26 cases (= 28 eyes) obtained from private sources:—

Mr. Bullar	1 case	No.	425 O.P.
„ Fisher	1 „	„	644 O.P.
„ Lang	2 cases	„	244 O.P.; 494 O.P.
„ Lawford	2 „	„	482 O.P.; 595 O.P.
„ Lawson	1 case	„	477 O.P.
„ Maddox	1 „	„	542 O.P.
„ Marshall	1 „	„	652 O.P.
„ Milligan	1 „	„	420 O.P.
„ Morton	2 cases	„	328 O.P.; 412 O.P.
„ Nettleship ...	1 case	„	397 O.P.
„ Parsons	1 „	„	657 O.P.
„ Ridley.....	3 cases	„	211 O.P.; 288 O.P.; 342 O.P.
„ Rockliffe	5 „	„	222 O.P.; 456 O.P.; H.R.I. (*a*); H.R.I. (*b*); 654 O.P.
„ Sinclair	1 case	„	541 O.P.
„ Spicer	1 „	„	358 O.P.
„ Tweedy	1 „	„	335 O.P.
„ Worth	1 „	„	650 O.P.

My best thanks are due to these gentlemen for allowing me to make use of their cases. In all instances, except where it is definitely stated to the contrary, the clinical diagnosis has been confirmed by the microscope. Cases presenting any doubtful features have been discarded.

* Read as a thesis for the M.B. degree before the University of Cambridge, July, 1905.

The object of the present paper is to bring up to date the subject of glioma in the Reports. It is based on lines precisely similar for the most part to the two preceding papers on the same subject. (*Vide* Ophthalmic Hospital Reports, vol. xiii; Notes on Glioma, with a Report of 60 Cases by Messrs. Lawford and Treacher Collins; also Reports, vol. xiv, Notes on Glioma Retinæ, by Mr. C. D. Marshall.)

The present paper differs from its predecessors in that a brief abstract is given, as far as possible in each case, of the curator's report, from the macroscopic as well as from the microscopic point of view. Inasmuch as it represents in a condensed form the more important details, it may prove of value to those who are unable to gain access to the museum reports, and who wish to compare the features of these cases with specimens elsewhere.

The conclusions to be drawn from the present series are practically identical with those stated in the two former papers already mentioned. The 60 cases reported by Messrs. Lawford and Collins occurred within the years 1871–1890. Five of these were obtained from private sources. The 32 cases reported by Mr. Marshall occurred between the years 1890–1896. Four were private cases. The 50 cases, which make up the present series occurred between 1896–1904. Twenty-four were patients at Moorfields. The remainder are obtained from private sources. Thus, during a period of 33 years, there have been 107 cases of glioma treated at this hospital:—

1871—1890	.....	55 cases in	19	years.
1890—1896	.....	28 „	6	„
1896—1904	.....	24 „	8	„
Total... 33 years		107 cases.		

The annual incidence in the present series is as follows:—

1896—1897	.....	2 cases.
1897—1898	.....	3 „
1898—1899	.....	4 „
1899—1900	.....	3 „
1900—1901	.....	0 „
1901—1902	.....	2 „
1902—1903	.....	8 „
1903—1904	.....	2 „
Total... 8 years		24 „

Sex.—Of the 50 cases now under consideration, 15 are males and 24 females. The sex in 11 cases is not stated. These figures show a decided preponderance of females. In the earlier papers, in one case males predominated, in the other the sexes were almost equally divided.

The following table shows the relative proportion of the sexes when a large number of cases are considered :—

Authority.	Males.	Females.	Not stated.	No. of cases.
Hirschberg	37	24	16	77
Vetsch	11	11	—	22
Lukowicz	11	15	1	27
Knapp	6	1	—	7
Lawford and Collins	30	27	3	60
Marshall	15	17	—	32
Wintersteiner	221	208	—	429
Present series	15	24	11	50
Total	346	327	31	704

The Eye Affected.—In the present series both eyes appear to have been involved in four cases only (viz., 5,610, 6,676, 425, O.P., 652, O.P.) The right eye alone was affected in 17 cases, and the left eye alone in 14 cases. In 15, the side involved is not mentioned. In view of the last statement, it would be unwise to draw any conclusions in regard to the proportion existing between bilateral and total cases. The usual figure given is one fourth. The figures appended below appear to bear out this statement for the most part :—

Authority.	Bilateral.	Unilateral.	Total cases.	Proportion of bilateral to total.
Lawford and Collins ...	12	43	55	1 : 4·58
Marshall	12	20	32	1 : 2·6
Wintersteiner	97	308	405	1 : 4·17
Hirschberg	14	46	60	1 : 4·2
Vetsch	1	21	22	1 : 22

Of the four cases where the disease was bilateral, in No. 5,610 the left eye had been shrinking since the child was 5 months old. A white spot had been noted in the R. when the child was was only 3 months old. Advice was not sought until the child was 2 years old. The left eye was then excised. Seven months later the child was rapidly wasting. The subsequent history is unknown.

In No. 6,676 we again have to deal with a shrunken globe (the right). The child had been blind in the right eye apparently since 8 months old. The right eye was removed at the age of 1½ years. The patient died about 6 months after the original operation.

In another case (O.P. 425) the left eye commenced to give trouble in May, 1900. It was enucleated in February, 1901. The right eye was noticed to be abnormal in January, 1900, the left media at that date being clear. In this case, then, although apparently the disease was first noted in the right eye, it made more rapid progress in the left. At the time the left eye was enucleated a mass of growth was left behind at the back of the orbit. This could not be removed.

No details of the course of Case 652, O.P., are given. Of the four bilateral cases just related, in one only (652, O.P.) were both eyes removed simultaneously.

Age at which the Growth became Apparent.—It would appear to be quite impossible to draw any accurate conclusions from a study of the dates, which are given in the fourth column of these tables. In many cases no mention is made, in others equivocal statements occur, *e.g.*, "Blind since 2 years"

(No. 5,585). Omitting then such cases, there are 21 cases (= 23 eyes) in which an approximate statement is made of the age at which the growth was first noted by the parents.

In the present series in no instance was an abnormal appearance noted actually at the time of birth.

In one instance only was the growth detected *before the first month.* In this case (Mr. Nettleship's case, 397, O.P.) the father was a medical man. He noticed a white reflex and vessels 3 or 4 weeks after birth. When 7½ weeks old the eye became rapidly inflamed and swollen. This subsided, however, in a few days. The eye, when removed, was small and shrunken. The optic nerve was apparently not involved. After history unknown.

In 3 cases attention was drawn to the eye between the first and second months of life (viz., Cases 5,299, 5,404, 335, O.P., at 6 weeks, 2 months, and 2 months respectively). The subsequent history of Case 5,299 could not be ascertained. The child was operated on when 12 weeks old.

Case 5,404 was operated on when 1½ years of age and was reported alive and well in February, 1905.

Case 335, O.P., was operated on when 3 months old; the growth having been noted 1 month previously. Exenteration was performed 6 weeks afterwards.

Between the second and fourth months, 2 cases (viz., 5,610, right eye; 425, O.P., right eye; at 3 months and 4 months respectively).

In both cases the two eyes were involved. Both patients are in all probability dead. In Case 5,610 this eye (the right) was not involved to the same extent as the left, although it was the eye to which attention was first drawn. For the history of the left eye see p. 328.

In Case 425, O.P., the right eye again was the first to attract attention. The left, however, was enucleated when the child was 1½ years old.

Three cases occurred between the fourth and sixth months of life; viz., 5,610, left; 425, O.P., left; 5,935; at 5 months, 6 months, and 6 months respectively.

The left eye of Case 5,610 was enucleated when the child was 2 years old. It was a shrunken globe. The left eye of Case 425, O.P., was removed when the child was $1\frac{1}{2}$ years old.

Case 5,935 was not operated upon till 2 years old and died within 7 months.

One case between 6 months and 1 year, viz., 5,639, at 8 months. This patient was operated upon when 11 months old. Unfortunately her subsequent history is unknown. The optic nerve was involved near the ocular end and showed much cell proliferation.

One patient at 12 months (viz., 288, O.P.). The eye was removed when $1\frac{8}{12}$ years old. Died 9 months after.

Between 1 year and $1\frac{1}{2}$ years, 2 cases (viz., Nos. 5,123 and 5,383, at 1 year and 3 months, and 1 year and 2 months). The former patient had her left eye enucleated when 2 years old. She is alive and in good health 7 years and 11 months after her operation. The latter patient was operated on when 3 years and 2 months old. No reply was obtained to enquiries in January, 1905. The optic nerve was apparently quite unaffected.

There are 2 cases occurring between $1\frac{1}{2}$ and 2 years (viz., Nos. 6,636 and 6,658: at 2 years and at 1 year 9 months respectively).

The former case was 3 years old when the right eye was removed. She died 2 months after the operation. The latter case was operated on 4 days after attention was first drawn to the condition, his age at that date being 1 year and 9 months. His subsequent history cannot be obtained.

Between 2 and $2\frac{1}{2}$ years, 1 case, No. 211, O.P., at $2\frac{1}{2}$ years exactly. The patient will be referred to subsequently. He is probably alive and well at the present. He was aged 3 at the time of operation.

Between $2\frac{1}{2}$ and 3 years attention was first attracted in 4 cases: viz., 5,545, 6,799, 6,834, H.R.I. (*a*), at $2\frac{10}{12}$ years, at $2\frac{11}{12}$ years, at $2\frac{9}{12}$ years, and $2\frac{7}{12}$ years respectively.

Case 5,545 was 3 years old at the operation and showed, 2 years afterwards, no sign of recurrence.

Case 6,799 was 3 years old when operated upon and was reported alive $8\frac{1}{2}$ months afterwards.

Case 6,834 was $3\frac{1}{2}$ years when operated upon.

Case H.R.I. (*a*) was 3 years old when operated upon and was alive and well 17 years afterwards.

Between 3 and 6 years there are 3 cases to be recorded: Nos. 222, O.P., 5,802, 6,425. At $3\frac{1}{2}$ years, $4\frac{1}{2}$ years, and $5\frac{11}{12}$ years respectively. The first case was operated upon when 4 years old and showed no recurrence 5 years afterwards. The second patient was $4\frac{1}{2}$ years when operated upon and is alive and well $5\frac{3}{12}$ years afterwards.

The third patient was 6 years old when operated upon. She was reported alive 6 months subsequently.

The above figures may be summarised as follows:—

Age at which growth was first noted.	Specimens, No. of.	
At birth	0	Within 1 year, 11.
Within 1 month	1	
Between 1—2 months	3	
2—4 „	2	
4—6 „	3	
6—12 „	2	
1 year—$1\frac{1}{2}$ years	2	Within 1—3 years, 9.
$1\frac{1}{2}$—2	2	
2 —$2\frac{1}{2}$	1	
$2\frac{1}{2}$—3	4	
3 —4	1	Within 3—6 years, 3.
4 —5	1	
5 —6	1	
	23 (21 patients).	

Recoveries and Duration of Life in non-Fatal Cases:—An attempt has been made to trace again several cases quoted in Mr. Marshall's paper. Many had already passed the three-year limit, which has been arbitrarily adopted as the time necessary to elapse before the patient is to be considered out

of danger. As a result of investigation, the figures below are obtained:—

No. 66.	Alive; no recurrence...	$13\frac{8}{12}$ years after operation.	
„ 68.	„ „ ...	$12\frac{11}{12}$	„ „
„ 69.	„ „ ...	$12\frac{7}{12}$	„ „
„ 71.	(double enucleation); no recurrence	$12\frac{1}{12}$ and $7\frac{2}{12}$	„
„ 72.	Alive; no recurrence...	$12\frac{1}{12}$	„ „
„ 74.	„ „ ...	$11\frac{11}{12}$	„ „
„ 78.	„ „ ...	$10\frac{7}{12}$	„ „
„ 83.	„ „ ...	$10\frac{2}{12}$	„ „
„ 86.	„ „ ...	$9\frac{4}{12}$	„ „

Of the unilateral growths:—

Case 69.—In November, 1897, this patient was reported to be "extremely ill, is delirious, and has convulsions." Mr. Marshall says, "it looks as if the period (three years) would have to be lengthened." The child, however, was alive and in good health in January, 1905.

Case 78.—Had just passed the three-year limit.

Case 83.—It was impossible to trace the patient when Mr. Marshall wrote his paper. Now, however, reported alive.

Case 86.—Had not passed the limit.

Of the bilateral growths:—

Case 71.—This was a double enucleation. It adds yet another case to his list of double enucleations (5 cases) who may be considered cured.

Case 84.—From a study of this case it would at first sight appear that the three-year limit was insufficient. The left eye was removed in February, 1895. In October, 1897, the child was in good health. The other eye, however, was seen to be involved. He died of a "lingering illness" on April 26, 1900, a period of five years after his original operation. The fact, however, we are dealing with a second eye must not be forgotten. Messrs. Lawford and Collins had 8 permanent recoveries. This figure includes one double enucleation. Vetsch gives 2 out of 25, Luke 5 out of 27.

With regard to recoveries and duration of life in non-fatal cases in the present series, observations must be limited for the most part to the 24 cases occurring in the actual practice of this hospital.

In January, 1905, 8 cases were reported alive.

They are:—

Case 5083	.....	8 years.
„ 5123	.....	$7\frac{11}{12}$ „
„ 5404	.....	7 „
„ 5802	.....	$5\frac{3}{12}$ „
„ 5966	.....	$4\frac{6}{12}$ „
„ 6555	.....	2 „
„ 6577	.....	$1\frac{10}{12}$ „
„ 6799	.....	$8\frac{1}{2}$ months.

From these figures it is seen that 5 have passed the limit. They are all cases with unilateral involvement.

Cases 5,610, 6,834, were known to be alive 7–8 months and 2 months respectively after operation. They are in all probability dead, but the actual date of death cannot be ascertained.

Case 5,548 was reported alive in January, 1901 (= $2\frac{4}{12}$ years after), but no reply was obtained to inquiries in January, 1905.

The subsequent history of 7 cases is quite unknown. Of the private cases, 3 have passed the limit.

222, O.P., known to be alive.....		$4\frac{1}{2}$ years after operation.	
H.R.I. (*a*)	„ „	6 „	„
H.R.I. (*b*)	„ „	6 „	„

Duration of Life in Fatal Cases.—Among the 24 hospital patients mentioned in this paper, 6 cases proved fatal. In 2 cases both eyes were involved. In addition to the 6, 2 are probably dead.

	Age at operation.	Died.
Case 5585	4 years	5 months after operation.
,, 5935	2 ,,	$6\frac{3}{4}$,, ,, ,,
,, 6248	7 ,,	$1\frac{5}{12}$ years ,, ,,
,, 6425	6 ,,	6 months ,, ,,
,, 6636	3 ,,	3 ,, ,, ,,
,, 6676	$1\frac{6}{12}$,,	$7\frac{3}{4}$,, ,, ,,

The intervals between the discovery of the growth in these cases and the operation are :—

Case 5585..... "Patient blind since 2 years old."
,, 5935..... $1\frac{1}{2}$ years' interval.
,, 6248..... Patient received injury 7 months prior to operation. Pain and swelling commenced 5 months after injury.
,, 6425..... 6 weeks' interval.
,, 6636..... 1 year interval.
,, 6676..... "Blind since 8 months old."

The corresponding figures in the non-fatal cases, for comparison, may be quoted here :—

	Age at operation.	Age when growth detected.	Interval.
Case 5083	$1\frac{10}{12}$ years	?	—
,, 5123	2 ,,	$1\frac{3}{12}$ years	9 months.
,, 5404	$1\frac{6}{12}$,,	2 months	$1\frac{4}{12}$ years.
,, 5802	$4\frac{1}{2}$,,	$4\frac{1}{2}$ years	—
,, 5966	2 ,,	No mention	—
,, 6555	$0\frac{1}{12}$,,	,,	—
,, 6577	6 ,,	Just under 6 years	—
,, 6799	3 ,,	$2\frac{11}{12}$ years	1 month.
,, 6834	$3\frac{1}{2}$,,	$2\frac{9}{12}$,,	9 months.

The longest interval between operation and death, from these figures, is $1\frac{5}{12}$ (6,248). In this case an injury appears to have drawn attention to the state of the eye. The shortest interval is 3 months (6,636). All the patients who

are dead were over $1\frac{1}{2}$ years when the operation was performed. In Case 6,425 the disease apparently was only noticed six weeks prior to operation. In one non-fatal case an interval of 1 year and 4 months elapsed between discovery and operation.

Among the fatal cases in Messrs. Lawford and Collins' series, the longest interval between death and operation was 1 year 2 months (Case 2).

In Mr. Marshall's series the figure is $2\frac{2}{12}$ years (Case 70) if we exclude Case 84.

Site of Recurrence.

Definite statements with regard to this point are as follows:—

1. Case 5,585 — A swelling was noted in the orbit. It grew very rapidly.
   „ 5,655 — The child died a few months after enucleation.

2. Case 5,610.—The left globe had been enucleated. There was a firm growth protruding from the lids 8–9 months subsequently. Actual date of death unknown.

3. Case 5,935.—The right globe had been enucleated, and the child died $6\frac{3}{4}$ months subsequently with large recurrence in the orbit. The end was ushered in with convulsions, and the patient died comatose.

4. Case 6,248.—The exenteration of the orbit was performed a few weeks subsequently to the primary operation. The child lived, however, as long as $1\frac{1}{2}$ years after the original operation.

5. Case 6,676.—In this case there was a *post-mortem*. Both orbits were full of glioma tissue. The anterior part of the scalp was infiltrated and thickened. The cranial bones and the chiasma were also involved. The inferior surfaces of the frontal lobes were pitted, but not involved.

6. Case 6,834.—Here exenteration was performed about 2 months after the primary operation. The socket was filled

with growth. The child complained of headache, and was vomiting. No secondary growths were detected. The subsequent history cannot be obtained.

7. Case 288, O.P.—In this case, 4 months after the original operation a recurrent growth was noted, as a growth over the nose. The second operation was performed 6 months after the original operation. The child died 11 weeks after the last operation.

The longest interval which elapsed between operation and recurrence in Messrs. Lawford's and Collins' cases was 9 months.

The intervals in the present series would appear to range from a few days to 8 or 9 months.

8. Case 456, O.P.—Recurrence was here noted at the apex of the orbit 1 month subsequent to primary operation. Exenteration was performed within a month from that date.

9. Case 654, O.P.—In this case, within 5 days recurrence was noticed. Exenteration had to be performed within a month of the primary operation.

On the Possible Shrinkage of Eyes.

No attempt will be made to discuss in this paper this important question. The reader is referred to the paper by Mr. Parsons, published in the Hospital Reports, vol. xvi, part 2. The whole question is there carefully considered, and a record of all such cases will be found. Suffice it here to say that one of the cases which tend to prove that glioma cells occur in shrunken globes is to be found in this present series, viz., No. 6,676. This patient is one of the 4 cases in which the tumour was bilateral. Mr. Parsons quotes full details of this case. The more important points, however, will be found in the tables.

In Case 5,610 we have to deal with a shrunken globe. In this case the left eye had been shrinking since 5 months old. A white spot had been noted on the right since the child was 3 months old. Microscopic examination showed small round cells and calcareous degeneration. The exact date of death

cannot be determined. In this case also both eyes were involved.

The left globe in Case 397, O.P. (a unilateral case) is reported to have been small and shrunken.

Temporary retrogression in glioma retinæ is stated to occur. In the present series of cases there would appear to be no grounds for proving or disproving the statement.

There is no evidence in favour of a spontaneous cure.

Family History.

It would appear that it is unusual for more than one member of a family to be afflicted with glioma retinæ. Messrs. Lawford and Collins in their paper say, "we have had no instance in which more than one member of the family has suffered from glioma of the retina" (Glioma Retinæ, Hospital Reports, vol. xiii, p. 21). Mr. Marshall in his article on this subject records the family history of one of his cases (Case 89) which is of extreme interest. A child, aged 2, had her right eye removed for glioma. At the operation the left eye was examined. It was found to contain a glioma. This eye was not removed; she died a few months later. The first child of this patient's family died at 2 years with convulsions; a white mass had been seen in the eye but no operation had been performed. The second child, a boy, died, aged 3 months, with convulsions. His eyes were not known to be affected. The third child, 15 years old in 1897, had an eye removed in Guy's Hospital. The appearance seen was similar to that seen in the first child's eye. The fourth and fifth children, aged 9 and 7 years, were both healthy and had no eye affection. The sixth is the patient, Case 89.

Mr. Marshall also quotes a case from Fuch's text book of Ophthalmology (p. 418), which is briefly as follows. The first child, aged 4, was a patient in which the right globe was removed. The growth had perforated the sclerotic. It died 6 months later. The second patient was a brother, aged

2 years. The patient's right eye was involved by a glioma. He died a year subsequently of a recurrent growth. The third child was brought for examination, but had only a coloboma of iris and choroid.

In the present series of cases the family histories are again of little or no import with one marked exception. For this case (211, O.P.) I am indebted to Mr. Ridley, who has kindly corroborated the details. Mr. Parsons in a clinical lecture upon glioma retinæ, delivered at the Great Ormond Street Hospital for children, says, "There is no case on record of a child from whom a gliomatous eye has been removed growing up and having children with glioma" (Clinical J., March 22, 1905). Mr. Ridley's case would appear to negative this statement.

The family history is briefly as follows:—A patient named Glover (a male) had his left eye removed for glioma, by Mr. Bowman, when 5 months old, in 1859. The diagnosis at this early date is, of course, open to doubt. He was reported alive and in good health in January, 1898.

The son of this man, Frank Glover (Case 211, O.P.) had his eye removed by Mr. Ridley on January 14, 1898, at the age of 3 years. "He was alive and well 2 or 3 years after the operation."

The sister of the first-named patient had two children. The elder, Nellie Wallbank, had the right eye removed when 4 years old, for glioma, by Mr. Hodges. She died 6 months later. The second child, Charlie Wallbank, had both eyes involved and died very shortly after the second eye had been removed. The family tree is as follows:—

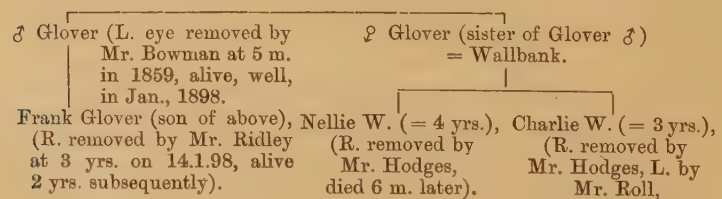

Many other authorities quote cases in which more than one member of the family were afflicted with glioma. Among these may be mentioned, v. Graefe, Calderine, Newton, Lerche, Sichel, Fuchs, Wilson. In one of Wilson's cases 8 children in one family were afflicted. The following remarkable family history of a case of Newton's is taken from the *Lancet* of November 22, 1902, being a quotation from the *Australian Gazette*. The patient, aged 2, was quite blind, having each eye occupied by a growth. She was the youngest of a family of 16. Of these 2 died in infancy from bronchitis—4 alive and well; 10, including the first-named patient, died of glioma; none lived beyond 3 years except one. That patient was operated on for unilateral growth and died aged 5. There were 3 unilateral and 7 bilateral cases. The eyeball ruptured in every case except one. The sexes were equally divided. An uncle in this family is said to have died in infancy with an eye complaint, the nature of which is not stated.

In the face of such evidence as this we may conclude that although, in the vast majority of cases, glioma only attacks a single member of a family, yet there is plenty of evidence to show that many members may be attacked.

It is, however, extremely rare for a patient with glioma subsequently to have a child who also develops it. It is presumably a family not a hereditary disease.

In conclusion I beg to offer my especial thanks to the following gentlemen:—To Mr. Herbert Parsons, for permission to study the museum reports and specimens, and for much valuable assistance. To Mr. Coats, for many kind suggestions. To Messrs. Rockliffe and Ridley, for the great trouble they took to furnish particulars, and corroborate the details of their cases.

SUMMARY OF CASES. Royal London

No. of case. Register No.	Name, surgeon, date.	Eye.	Age when growth first noted.	Age at operation.	Duration of life after operation.	Date of first sign of recurrence. Sites of recurrence.	Tension.
1 5083	Richard Bird Mr. Tweedy 5.1.97	?	?	$1\frac{10}{12}$	8 yrs.	None	T. +
2 5123	Rose Babir Mr. Silcock 26.2.97	L.	8 or 9 m. ago "white appearance; red last 5 wks."	2 yrs.	$7\frac{11}{12}$	None	T. +
3 5299	Eva Wayth Mr. Lang 30.9.97	L.	"5—6 wks. ago; seemed to grow v. rapidly after first noted; apparently painless."	12 wks.	...	...	T. + 2

Ophthalmic Hospital. 1897—1905.

Summary of Curator's Report.	Family history.	Remarks.
Conjunctiva œdematous; cornea steamy; contents of A.C. appear blood-stained; pupil dilated. *Section.*—Lens displaced back. Vitreous occupied by large solid mass; loose, friable, nodulated; colour: dirty white; mass occupies two-thirds of globe; remaining one-third filled with loosely coagulated albuminous material. *Micro.*—A.C. deep. Angle quite obliterated. Iris displaced back. O.N.: intra-ocular part involved, but extra-ocular not; nerve cut long. Growth springs apparently from posterior pole of eye.	No mention	10.1.05 no recurrence.
Cornea, lens, clear; A.C. normal; large yellowish mass to be seen behind lens; seems to have blood extravasated on surface. *Section.*—A.C. normal in depth; angle quite closed by adhesions between iris and cornea. Lens *in situ.* Vitreous: two-thirds occupied by large glioma, which is covered with hæmorrhages. It extends over two-thirds of retinal surface. Portion runs forward in hyaloid canal. O.N. cut very short indeed. *Micro.*—Ant. angle closed by adhesions. Iris somewhat atrophied. Ectropion of uveal pigment. O.N. apparently involved. Growth springs from vitreous surface of retina; glioma endophytum. Much degeneration.	Mother healthy; no miscarriages. Three children by first husband, one (the patient) by second. —— No previous history of eye affection in children.	L. eye never inflamed; R. eye apparently healthy. January, '05 alive, well.
Cornea hazy; A.C. shallow; large growth seen in eye. *Section.*—Angle A.C. closed; iris and cornea in contact. Lens pushed forward to back of iris. Globe filled three-quarters with solid glioma. Retina, where recognised, entirely detached. Running from optic disc to back of retina is the central artery. Choroid much atrophied. *Micro.*—Growth much degenerated. Cells are of small, round variety; vascular in parts.	Father healthy; parents not blood relations. Patient is second child; elder child, 18 months, healthy. No F. H. of eye affection.	Written to January, '05. No reply.

SUMMARY OF CASES. Royal London

No. of case. Register No.	Name, surgeon, date.	Eye.	Age when growth first noted.	Age at operation.	Duration of life after operation.	Date of first sign of recurrence. Sites of recurrence.	Tension.
4 5383	Arthur C. Outen Mr. Tweedy 25.1.98	R.	White mass; seen 1 yr. ago. No notice taken till 6 wks. ago.	$3\frac{2}{12}$	$7\frac{1}{3}$ yrs.	None	T. n.
5 5404	Daisy Lovegrove Mr. Lang 21.2.98	R	First noticed when 2 m.	$\frac{10}{12}$	7 yrs.	...	T. +
6 5545	Douglas Vincent Mr. Lawford 10.9.98	R.	White spot detected 8 wks. ago	3 yrs.	...	...	T. n.

Ophthalmic Hospital. 1897—1905.

Summary of Curator's Report.	Family history.	Remarks.
A.C. (?) shallow. White floating mass seen. *Section.*—A.C. normal in depth; iris healthy; lens *in situ.* Vitreous: About four-fifths occupied by partially detached retina; from inner surface of which grows large diffuse gliomatous-looking mass. Whole retina involved; it is thickened; on one side mass nearly extends up to the ant. posterior diameter. Choroid not involved. O.N. cut long; not swollen. *Micro.*—Angle of A.C. narrow, but open; no evident iritis or cyclitis. Retina: detached, thickened, thrown into folds. Growth shows much degeneration, also small round cells, identical with ordinary exudation cells. O.N. apparently quite unaffected.	Father and mother healthy. No consanguinity. One child died æt. 1 year. Patient is eldest child.	Patient had trouble with eyes during first week of life, viz., profuse discharge. Recovery within 3 weeks. Nothing noticed until 1 year ago. Patient has never complained of the eye. May, '05. In good health. Socket normal. L = 6/6 vision.
Cornea hazy. Eye enlarged. Vertical = 13·5 mm. Ant.-Post. = 24·5 mm. Transverse = 22 mm. *Section.*—Ant. chamber normal depth; angle closed; lens *in situ*; choroid *in situ.* Vitreous entirely filled with large tumour; partly opaque, partly transparent; only little degeneration; vessels and vascular spaces seen. Retina invisible. *Micro.*—No report.	Patient is eleventh child. One died 8 months old (lung trouble). Rest healthy. No eye affection.	Child never appeared to suffer much pain. L. eye apparently healthy. Alive 20.2.05. Socket normal. L. normal.
Anterior part eye apparently healthy. Yellowish mass can be seen in lower vitreous. *Section.*—Cornea clear; ant. chamber normal; angle open; lens clear, *in situ.* Vitreous chamber much diminished in size owing to large tumour; soft; vascular, flocculent; whitish-yellow in colour; tinged with hæmorrhages interiorly; shows much degeneration. Growth reaches from back of iris to point just posterior to equator of globe. Retina: greater part *in situ*, except at anterior part, where it is detached with choroid. Shows outlying nodules.	Nothing stated ...	16.1.01. No sign recurrence. L. eye healthy. Not heard January, '05.

SUMMARY OF CASES. Royal London/

No. of case. Register No.	Name, surgeon, date.	Eye.	Age when growth first noted.	Age at operation.	Duration of life after operation.	Date of first sign of recurrence. Sites of recurrence.	Tension.
5545	Douglas Vincent —*continued.*						
7 5585	Arthur Stanton Mr. Lawford 27.10.98	L.	L. been blind 2 yrs. Painful for 6 wks.	4 yrs.	...	...	T. + 2
5655	Mr. Lawford 15.2.99	...	...	5 yrs.	5 m.	3 wks. ago swelling noticed in orbit. Has grown very rapidly.	...
8 5610	May Wallis Mr. Silcock 2.12.98	L. and R.	L. been shrinking since 5 m. old; white spot noticed in R. since 3 m. old.	2 yrs.	?	...	Not mentioned.

Ophthalmic Hospital. 1897—1905.

Summary of Curator's Report.	Family history.	Remarks.
O.N. not obviously affected; is cut off flush with sclerotic. *Micro.*—Small round cells; patchy areæ of degeneration; growth springs apparently from extreme inner surface of retina; greater part of retina appears healthy.		
Eye very much enlarged. Cornea hazy; eye apparently full of growth, yellowish in colour. Annular staphyloma in ciliary region. O.N. much enlarged. *Section.*—Sclerotic, much stretched, thinned, especially in ciliary region. Iris much displaced to each side, so that it forms part of the ciliary staphyloma. Lens pushed forward; in contact with back of cornea. Remainder of globe filled with large gliomatous mass; consists of two parts, inner and outer; former is in vitreous chamber, much degenerated; has calcareous appearance, bounded externally by choroid; sharply limited from rest of growth; latter composed of more recent tissue; is translucent; has numerous small degenerated areæ. Several small hæmorrhages. Lamina cribrosa has given way. Growth continued along optic nerve, which is entirely occupied by glioma cells. Growth must have extended very far back.	No mention.	
Contents of orbit removed, but not completely. Stump could not be removed. *Micro.*—Typical glioma, with much degeneration.	. .	Patient died 31.3.99.
L. globe much shrunken; nothing can be seen owing to blood in A.C. *Section.*—Sclerotic; cornea, much thickened; shrunken. Iris hardly distinguished. Vitreous absent. Retina cannot be distinguished. Choroid somewhat detached. Interior globe solid with dense material containing numerous calcareous nodules.	No mention	No reply January, '05.

SUMMARY OF CASES. Royal London

No. of case. Register No.	Name, surgeon, date.	Eye.	Age when growth first noted.	Age at operation.	Duration of life after operation.	Date of first sign of recurrence. Sites of recurrence.	Tension.
5610	May Wallis—*continued.*					25.7.99. L. lids protruding with twin growth. Child wasting rapidly; appears to be in great pain.	...
9 5639	Ella Kitchener Mr. Spicer 11.1.99	R.	White mass 3 m. ago. Been increasing last 4 wks.	$\frac{11}{12}$	...	...	No mention.
10 5802	Grace Combes Mr. Gunn 7.10.99	R.	14 days ago something noticed in front of eye.	$4\frac{1}{2}$	$5\frac{3}{12}$ yrs	...	T. full

Ophthalmic Hospital. 1897—1905.

Summary of Curator's Report.	Family history.	Remarks.
Micro.—Small round cells; calcareous degeneration; whole eye involved; no structure recognisable; cannot say where growth commenced. 25.7.99. R. pupil widely dilated; yellow reflex.		
White mass to be seen in vitreous. Lens, cornea, clear; A.C. normal. *Section.*—A.C. normal; angle open. Lens normal, *in situ.* Large glioma situated on nasal side of eye. Shows typical degenerated patches. It covers the optic nerve. Choroid, *in situ.* Sub-retinal space filled with albuminous material. O.N. divided far back. Impossible to say if nerve is involved. *Micro.*—Anterior eye healthy; large glioma grows from nasal retina; much degenerated. Choroid not involved. O.N. involved near ocular end. Shows much cell proliferation.	Father, mother, healthy. No consanguinity. Patient youngest of 10. Seven still alive. Third and sixth died (lungs), eighth cross-eyed, since wh. C.	There has been discharge from ears 6 months. No fits. No reply January, '05.
Grey opacity to be seen; shakes on movement of eye; surface irregular; shows hæmorrhages; eye normal to external appearances. *Section.*—Anterior angle slightly restricted; lens much flattened; clear. Flocculent white mass occupies fully three-fourths of interior of globe; typical degenerated areæ. Retina intact, but infiltrated with growth, dense and white. O.N. cut only 3·5 mm. from retina. Much infiltrated with growth. *Micro.*—Anterior eye healthy; angle A.C. narrow; vitreous occupied by large glioma, which grows from retina; unaffected retina thickened; choroid *in situ.* O.N. infiltrated up to point of section.	No mention	Alive 28.1.05. L. eye normal.

SUMMARY OF CASES. Royal London

No. of case. Register No.	Name, surgeon, date.	Eye.	Age when growth first noted.	Age at operation.	Duration of life after operation.	Date of first sign of recurrence. Sites of recurrence.	Tension.
11 5935	May Johnson Mr. Lawford 9.5.00	R.	R. wrong since 6 m. old.	2 yrs.	6¾ m.	Large recurrence in orbit. Patient died with convulsions and comatose.	T. +1
12 5966	E. May Gowling Mr. Morton 10.7.00	R.	No mention	2 yrs.	...	...	No mention.

Ophthalmic Hospital. 1897—1905.

Summary of Curator's Report.	Family history.	Remarks.
A.C. now deep; pupil dilated, oval, long axis horizontal. Yellowish white reflex from back lens. Yellowish growth seen protruding through centre of O.N.	Patient one of three living. Two (twins) died at 6 and 9 months.	Before operation. R. deviates in. Cornea clear. A.C. shallow.
Section.—Iris adherent at angles to cornea. Lens shrunken; pulled back from iris. Retina detached; from it springs white flocculent mass extending into vitreous and into subretinal space. Surface choroid involved, but is *in situ;* O.N. involved.		Pupil immobile, dilated, regular. Large white mass seen; irregular flocculent. No red reflex. No P.L. Left cornea clear.
Micro.—Retina greatly degenerated. Various layers not to be differentiated. In most parts one thick layer of deeply-staining nuclei is visible. Growth chiefly endophytic; shows much degeneration; spreads forwards along hyaloid membrane from ora serrata to back of lens. O.N. shows growth occupying its centre with small amount of apparently degenerated fibres round margin.		Good A.C. Pupil active. Fundus not examined. Father thinks child has had pain. Died 30.11.00.
A.C. shallow. Iris clear; no retraction at base; whitish-yellow reflex—more or less irregular three-lobed appearance, in which some blood-vessels are seen. *Section* (Horizontal).—Eye nearly full of white flocculent growth. A.C. nearly obliterated. Lens, yellow, misshapen. Posterior surface drawn back into peak at point where retina passes back to O.N. Retina detached; seat of growth; choroid *in situ;* O.N. apparently not infiltrated. *Micro.*—Shows exophytic growth. At one spot layers of retina seen to be involved. Growth seems to spring almost entirely from inner nuclear layer. Inner G. layer invaded also G. and N.F. layers. Eventually comes to lie next to vitreous. No rings of cells. Cells grouped round blood-vessels. Little degeneration only.	F. labourer ..... Other children healthy. No eye affection.	Before operation. Three-lobed yellowish mass seen by oblique illumination. Alive, well, 28.1.05. Good health since operation. Left eye examined by medical man. Said to be normal. R. socket healthy.

SUMMARY OF CASES. Royal London

No. of case. Register No.	Name, surgeon, date.	Eye.	Age when growth first noted.	Age at operation.	Duration of life after operation.	Date of first sign of recurrence. Sites of recurrence.	Tension.
13 6248	Maddie Widdick Mr. Gunn 12.10.01	R.	2 m. ago pain, swelling commenced. Pain in eye 7 m. ago; became bloodshot.	7 yrs.	$1\frac{6}{12}$ yrs.	...	No mention.
6248A	23.10.01	...	...	...	...	Recurrence in orbit. R. orbit exenteration, 23.10.01.	...
14 6425	Amy Sylvester Mr. Morton 29.7.02	L.	L. noticed different from R., 6 wks. Pain at times.	6 yrs.	...	...	T. ? >R.

Ophthalmic Hospital. 1897—1905.

Summary of Curator's Report.	Family history.	Remarks.
Globe fully twice normal size. Lobulated growth on nasal side. O.N. cut long, but obviously much enlarged; infiltrated with growth. *Section* (Horizontal).—Globe filled with lobulated growth, only lens, cornea, with parts of sclerotic to be distinguished. O.N. much swollen; gelatinous; infiltrated. Large mass of growth stretches forward from disc to lens. *Micro.*—Section of posterior pole shows well-marked intra- and extra-ocular glioma. Central mass grows forwards from disc. On each side is a mass sharply cut off which replaces choroid. It is covered with normal lamina vitrea and normal retinal pigment epithelium. Growth atypical glioma with large eosine staining degenerated areæ. Some areæ show well-marked pigmentation. Increase in O.N. due to large sheath of growth; true nerve being degenerated. Lids and orbital contents:— Lachrymal gland and O.N. hard. Other tissues seem normal; L. gland inflamed, invaded with leucocytes. Nerve at back of orbit surrounded with large mass of growth. Glioma probably already intracranial.	No mention	Before operation. Has had headache, giddiness for 2 months. Vomiting nearly every day for 3 weeks. R., considerable proptosis. Nasal side swollen, lobulated. Cornea rotated out, opaque. L., pupil reacts. ... Death, 26.4.03, "from the effects of her eye."
Left cornea now clear. ? haze due to tension. White flocculent coagulum in lower part A.C. One small round mass readily moves about in aqueous. White material seen in fundus. *Section.*—Cornea good. A.C. good. Globe nearly filled with white growth. Retina can only be traced in places. Choroid invaded below. O.N. invaded. *Micro.*—A.C. normal. Both angles blocked by adhesions of iris to cornea. Flocculent mass in lower angle consists of cells of varying size, shape; also pigment granules. Iris normal. Vitreous full of glioma; shows comparatively little degeneration. Typical columns and ring cells arranged round blood-vessels.	Phthisis in family	Before operation. L., cornea hazy. A.C. shallow. Pupil dilated; inactive. Iris vascular. Yellow-greyish reflex. Large irregular nodular masses with considerable vascularity. No tenderness. R., cornea clear. Iris normal. Fundus normal. Died 25.1.03.

SUMMARY OF CASES. Royal London

No. of case. Register No.	Name, surgeon, date.	Eye.	Age when growth first noted.	Age at operation.	Duration of life after operation.	Date of first sign of recurrence. Sites of recurrence.	Tension.
14 6425	Amy Sylvester—*continued.*						
15 6536	Lily Gourd Mr. Spicer 7.1.03	R.	No mention	3 yrs.	...	...	No mention.
16 6555	Bertram Mulloch Mr. Lawson 23.2.03	L.	No mention	$\frac{9}{12}$	...	...	No mention.
17 6577	Bella Nisbet Mr. Spicer 28.3.03	L.	12.3.03. Vision in L. found defective. 14.3.03. O.P.	6 yrs.	$1\frac{10}{12}$ yrs.	...	T. full.

Ophthalmic Hospital. 1897—1905.

Summary of Curator's Report.	Family history.	Remarks.
Growth entirely endophytic. O.N. infiltrated with growth anteriorly. Cut end and posterior 3 mm. are normal.		
Section (Down and out).—Cornea ; A.C. ; iris ; lens ; all normal. Large grey, dead-white tumour situated on outer side ; grows from retina. Base = 11 mm. Thickness = 13 mm. Front of base is 4 mm. from angle of A.C. Growth nearly touches back of lens. Has very white patches on it, characteristic of glioma. Unusually isolated for a glioma ; no visible satellites. Growth far from nerve. Remaining retina *in situ*. One wavy distended vessel passes from disc on to tumour. Choroid is *in situ*. *Micro.*—Glioma endophytum ; no rings ; no satellites. O.N. normal.	No mention	Before operation. R., cornea clear. A.C. good. Iris normal ; no retraction at periphery. White glistening nodular mass in vitreous on outer part. L., normal.
Section (Sagittal).—A.C. shallow. Vitreous full of glioma ; no evidence of extra-ocular extension. *Micro.*—A.C. shallow ; angle blocked. Glioma fills globe. Chiefly endophytic ; much degenerated.	No mention	Before operation. 16.2.03. L., A.C. very shallow. ? glioma. 21.2.03. L. > R. Cornea clear. A.C. shallow. Pupil smaller than R. Iris discoloured. White opaque mass behind pupil. January, '05. Alive, well. Socket said to be healthy by medical man.
Section (Down and in).—Glioma forms thick cap inside posterior part of sclerotic ; many hæmorrhages. Cornea very slight œdema. A.C. one angle. *Micro.*—Compact cellular tissue, and very early adhesions of iris. Iris normal. Lens shows early peripheral changes. Retina almost entirely gliomatous (endophytic). Choroid not involved. O.N. involved near disc. Cut end normal.	No mention	Before operation. 24.3.03. L., no retraction of iris at periphery ; dull brown ; reacts consensually. Nodular mass projects into vitreous, down and in. R., iris bright, grey. T. n. Alive, well, 28.1.05.

SUMMARY OF CASES. Royal London

No. of case. Register No.	Name, surgeon, date.	Eye.	Age when growth first noted.	Age at operation.	Duration of life after operation.	Date of first sign of recurrence. Sites of recurrence.	Tension.
18 6636	May Moore Mr. Morton 11.8.03	R.	Coming on 12 m.	3 yrs.	3 m.	...	T. +
19 6658	Thomas Martingale Mr. Fisher 19.9.03	R.	White reflex noticed 15.9.03.	$\frac{9}{12}$	...	...	T. n.
20 6667	Ellen Hellyer Mr. Lang 28.9.03	R.	Has squinted 6 m.	1 yr.	...	...	No mention.

Ophthalmic Hospital. 1897—1905.

Summary of Curator's Report.	Family history.	Remarks.
Globe and orbital contents:— A.C. deep; angles adherent. There are pearly points; degenerated areæ. Retina extensively involved. Growth just external to O.N. is extrascleral. O.N. sheath involved. Vaginal space filled with tumour tissue. *Micro.*—Cornea with epithelium gone; œdematous. Pus shows peripheral anter. synechiæ each side. Ectropion uveal. Lens cortex largely homogeneous. Ciliary body degenerated. Postero-ext. part involved. Globe nearly full; much degenerated glioma. Choroid largely replaced by glioma. O.N. head involved, also posterior part near cut end. Large extra-ocular growth behind.	No mention	Influenza Easter. Before operation. R., no injection. Proptosis. Cornea clear Green reflex. T. +. L., normal. Died 10.11.03.
Section (Sagittal).—A.C. shallow; iris normal; also lens. Retina completely detached, especially below. Choroid: white over whole lower part, with sharply defined edges. ? coloboma. *Micro.*—Cornea normal. A.C. shallow. Angles open. Lens: cortex cataractous. Retina completely detached; glioma exophytum. Choroid shows nodules on inner surface. No coloboma.	No mention	Before operation. R. A.C. shallow. Iris bright. Lens clear; yellow irregular mass with vessels over it. L. normal. No reply January, '05.
Section (Horizontal).—A.C. contains blood. Iris has white nodules near pupil. Lens *in situ*. Retina detached—trumpet shaped. Large mass of glioma round disc. Many satellites behind retina and on choroid; latter degenerated. *Micro.*—Cornea: some œdema. A.C., angles full of glioma, which also extend along back of cornea. Hyphæma. Iris covered and involved; lens degenerated. Ciliary body a mass of glioma. Choroid involved. O.N. much degenerated. Anterior part full of growth.	—	Before operation. R. chemosis. Cornea hazy. Pupil dilated; old hæmorrhage. Greenish-white reflex. L. normal. No reply January, '05.

SUMMARY OF CASES. Royal London

No. of case. Register No.	Name, surgeon, date.	Eye.	Age when growth first noted.	Age at operation.	Duration of life after operation.	Date of first sign of recurrence. Sites of recurrence.	Tension.
21 6673	Ellen Hooper Mr. Collins 5.10.03	R.	23.7.03. R. eye struck 6 wks. ago by corner of chair; became inflamed.	3 yrs.	...	...	T. n. or +
22 6676	Edith Hopping Mr. Gunn 7.10.03	R. and L.	Blind since measles at 8 m., and eye usually kept closed since pneumonia 6 wks. ago.	$\frac{16}{12}$	...	12.3.04. Recurrence in R. socket. 6.10.04. Contents of R. orbit protruding through palpebral fissure in fungating mass.	T. —

phthalmic Hospital. 1897—1905.

Summary of Curator's Report.	Family history.	Remarks.
Section (Sagittal).—A.C., one angle blocked. Lens *in situ*. Retina detached; extensive glioma exophytum. Choroid *in situ*; no visible deposits. O.N. infiltrated in anterior part. *Micro.*—Both angles A.C. blocked by peripheral anterior synechiæ. Glioma cells in lower angle. Iris. Ectropion uveæ. Cil. body degenerated. Choroid not affected. No nodules on surface of Bruch's membrane.	Two other children healthy	Before operation. R. A.C. shallow. Iris pushed forward, discoloured; fine vessels on it below. Pupil well dilated. Yellow-white reflex; vessels on surface below. L. normal.
Right globe: shrunken. Antero-posterior = 16 mm. Transverse = 18 mm. Vertical = 16 mm. *Section* (Sagittal).—Cornea very thick. A.C. absent. Iris pushed forward. Lens, large cataractous. Behind lens is yellowish-white mass with reddish spots on it; uveal pigment surrounds it. *Micro.*—Cornea: epithelium thin, ill-formed; Bowman's membrane v. wavy. Subst. Propria much thickened, vascularised, œdematous. Descemet wrinkled; endothelium present only in places; microscopic deposit of pigment. A.C. small, irregular. Iris is transformed into hyaline fibrous tissue, with pigment in meshes—horizontal long rod-shaped nuclei—is adherent everywhere to capsule of lens. Lens cataractous. Ciliary B. detached posteriorly; much degenerated. Choroid: congested, degenerated; condition is characteristic of phthisis bulbi. Retina cannot be recognised, except pigment cells. Internal to choroid is layer of new formed connective tissue; irregular in thickness; greater everywhere than that of underlying choroid. Tissue vascular; highly cellular. Spindle cells and asteroid cells with long nuclei. Outer boundary formed by nearly continuous coal black pigment epithelium (retinal).	Four other children. No miscarriages. All good sight.	Before operation. R. much shrunken, much infected. Cornea hazy. A.C. shallow. Iris bluish-green, vascular. Lens ? opaque. Fine vessels run on to capsule. No reflex. T. —. L. cornea clear. A.C. shallow. Iris discoloured, vascular. Yellow reflex. Hæmorrhages. T. n. 12.3.04— L. eye full; œdematous. Conjunctiva protruding. elastic swelling to be felt. Cornea enlarged. Iris discoloured. Yellowish reflex behind clear lens. 6.4.04— L., marked proptosis; fungating mass above, below. Cornea dry, ulcerated. 8.4.04— L. eye proptosed and perforated. 30.4.04. Death. For full description and discussion on shrunken globes, *vide* O. H. Rep., vol. xvi, pt. 2. "Case of great importance as an almost incontestable

SUMMARY OF CASES. Royal London

No. of case. Register No.	Name, surgeon, date.	Eye.	Age when growth first noted.	Age at operation.	Duration of life after operation.	Date of first sign of recurrence. Sites of recurrence.	Tension.
22 6676	Edith Hopping —*continued.*						
23 6799	Caroline Newman Mr. Lawford 14.5.04	R.	R. noticed different from L. 2—3 wks. Measles followed by pneumonia 12 m. ago.	3 yrs.	8½ m.	...	T. + 1.
24 6834	Lazarus Wineberg Mr. Gunn 18.6.04	L.	27.9.03 Small red spot noticed. Violent retching day before commencement.	3½	...	22.8.04. Socket filled with growth in last fourteen days. Child complains headache — no vomiting, no secondary growths detected.	...

Ophthalmic Hospital. 1897—1905.

Summary of Curator's Report.	Family history.	Remarks.
Vitreous: whole cavity filled with granular material, staining with eosine; this composed of degenerated cells. O.N. atrophic, highly cellular. Cell nuclei vary greatly; most oval, faintly staining; probably neuroglial; others rod-shaped, deeply staining, of connective tissue origin; others small, round, deeply stained, probably gliomatous. Orbital intra-cranial extensions show typical features of glioma retinæ as it occurs in extra bulbar extensions. *Post-mortem* note. Head only examined:—Both orbits full of gliomatous tissue. Anterior part of scalp infiltrated and thickened; also cranial bones, chiasma. Roofs of orbit raised. Inferior surface frontal lobes pitted, but not involved.		case of glioma in a shrunken globe."
Section.—A.C. good. Lens shows changes. Retina: large mass of glioma in posterior part. Choroid *in situ.* *Micro.*—Not given.	Three other children alive.	Before operation. R. cornea hazy. A.C. good. Pupil dilated. ? Mydriatic. Does not react. Iris dull, vascular; Yellow reflex with white nodular streamers. No vessels or hæmorrhages seen. L. normal. Reported alive, well, 30.1.05.
Section.—A.C. absent. Lens cataractous; in contact with cornea. Retina forms large antero-posterior band of glioma. Choroid *in situ;* full of secondary nodules; larvæ ciliary staphyloma below. *Micro.*—Not given.	...	Progress of case. 3.10.03 = O.P. L. hyphæma (started as small red spot 1 week previously. Violent retching on previous day). 10.10.03. L. paracentesis. Iris discoloured, tremulous; yellow reflex from movable mass in vitreous. 18.6.04. L. ciliary staphyloma below. Cornea hazy. No A.C. Iris irregular, dilated, discoloured. Lens opaque. No reflex.

SUMMARY OF CASES. Royal London

No. of case. Register No.	Name, surgeon, date.	Eye.	Age when growth first noted.	Age at operation.	Duration of life after operation.	Date of first sign of recurrence. Sites of recurrence.	Tension.
24 6834	Lazarus Wineberg —*continued.*						
25 211	Frank Glover Mr. Ridley's case 14.1.98	R.	Mass noted 6 m.	3 yrs.	...	...	No mention.
26 222	Jessie Wright Mr. Rockliffe's case April, '98	?	6 m. ago.....	4 yrs.	...	...	?
27 244	? name, sex Mr. Lang's case June, '98 Middlesex Hospital	?	?	?	...	...	?
28 288	Charles Beniston Mr. Ridley's case 21.1.99	L.	At 12 m. ...	$1\frac{8}{12}$ yrs.	approx. 9 m.	At 2 yrs. age growth over nose remarked (secondary). $2\frac{2}{12}$ yrs. removed. Death 11 wks. after.	?

Ophthalmic Hospital. 1897—1905.

Summary of Curator's Report.	Family history.	Remarks.
		22.8.04. See p. 34. R. is normal. 24.8.04. Exenteration L. orbit. Jan. '05, no reply.
A.C. almost obliterated. Retina entirely detached. Growing from outer surface is diffuse mass. *Micro.*—Cornea, iris, adherent; much atrophied; angle A.C. closed. Cil. body much atrophied. Difficult to say from which surface retina growth originates; probably outer; all appearances of glioma retinæ. O.N. head involved; ? the rest.	Family history very interesting:— ♂ Glover (L. eye removed in 1859 at 5 m. by Mr. Bowman, alive, well, Jan., '98. Frank Glover (son of above), R. removed by Mr. Ridley, æt. 8 yrs., on 14.1.98. "Alive and well a year or two after." — Mr. Ridley. ♀ Glover = Wallbank. Nellie (= 4 yrs.), (R. removed by Mr. Hodges, died in 6 m. after op.) Charlie (= 3 yrs.), (R. removed by Mr. Hodges, L. by Mr. Roll, died in 6 m.	
A.C. normal depth; angle open. Vitreous three parts full; large white growth. O.N. enlarged; semi-opaque. *Micro.*—Tumour a glioma, arising apparently from choroidal surface of retina. Growth v. extensive. O.N. much involved. Growth extends beyond point of section.	?	Child healthy. No recurrence March, '03.
Section.—A.C. normal depth; angle seen open. Vitreous two-thirds filled with dense white growth; numerous areæ of degeneration. O.N. obviously involved. *Micro.*—Typical glioma. O.N. involved to cut end.	?	
Cornea clear; A.C. shallow; angle appears closed; vitreous absent. Retina for most part cannot be recognised; detached; rest involved in large glioma; dense white colour; shows much degeneration. *Micro.*—Small round-celled glioma.		

SUMMARY OF CASES. Royal London

No. of case. Register No.	Name, surgeon, date.	Eye.	Age when growth first noted.	Age at operation.	Duration of life after operation.	Date of first sign of recurrence. Sites of recurrence.	Tension.
29 328	? name ? sex Mr. Morton's case June, '99	?	?	?	...	...	?
30 335	—— K. ? sex Mr. Tweedy's case July, '99	?	First symptom noted when 2 m. Detached retina noted July 6. Enucleation 9.7.99. Exenteration 20.8.99, by Mr. Horsley.	3 m.	...	...	?
31 342	? name Mr. Ridley's case Sept., '99	...	...	...	...	...	?
32 358	? name Mr. Spicer's case 1900	?	?	?	?	...	?
33 397	—— M. Mr. Nettleship Nov., '00	L.	White reflex with vessels seen by father 3 or 4 wks. after birth.	Infant	...	...	T. —.
34 412	Grace S. Mr. Morton's case Jan., '01	L.	?	?	...	...	?

Ophthalmic Hospital. 1897—1905.

Summary of Curator's Report.	Family history.	Remarks.
Front part eye apparently healthy; vitreous two-thirds full large growth, which is whitish on surface. Pigmented and degenerated in parts. O.N. at point of entrance much enlarged. *Micro.*—Glioma. O.N. much enlarged.	Parents ∞.	
Eye examined by Mr. Lister: "It is glioma of retina." O.N. involved. *Micro.*—Recurrent glioma R.	Father a medical man.	
Retina seems to be studded with discrete white mould-like gliomatous growths. *Micro. Section* through ora serrata, shows thickening in external and internal nuclear layers. Whole retina involved in growth.		
Eye small, shrunken. Globe contains a very friable white substance. Retina appears detached. Cornea opaque. *Micro.*—Growth a glioma R., much degenerated. Difficult to say whether endophytic or exophytic. Shows rings of columnar cells. Probably chiefly endophytic. O.N. apparently not involved.	Father a medical man.	At 7½ weeks eye rapidly inflamed, swollen, chemosis; went down in few days. L. cornea semi-opaque. T. — somewhat.
Eye small. A.C. absent. Lying external to retina is large whitish growth, mottled on surface, choroidal surface covered over with white ivy-like growth for considerable extent. *Micro.*—A glioma. Growth involves nerve-fibre layer as if it were grown from this layer. O.N. not involved.	?	

SUMMARY OF CASES. Royal London

No. of case. Register No.	Name, surgeon, date.	Eye.	Age when growth first noted.	Age at operation.	Duration of life after operation.	Date of first sign of recurrence. Sites of recurrence.	Tension.
35 420	? name Dr. Milligan's case Feb., '01	?	?	?	...	...	?
36 425	Arnold L. Mr. Bullar's case 28.2.01	R. and L.	March, '00. Something wrong with R. 2 m.; under homatropine a dislocated white lens; L. media clear. May, '00, began to go.	1½ yrs.	...	...	...
37 456	George Smith Mr. Rockliffe's case 7.3.02 Shown Ophth. Soc. 30.4.02 *Vide* Appendix Vol. 22	R.	...	3 yrs.	...	Recurrence first noticed 7.4.02. at apex of orbit. Apr. 22, size of walnut. Apr. 28, double in size. May 3, exenteration.	...
38 477	? name Mr. Lawson's case June, '02	?	?	?	1 m. or under.	...	...

Ophthalmic Hospital. 1897—1905.

Summary of Curator's Report.	Family history.	Remarks.
Micro.—Cornea N. A.C. angle closed. Vitreous absent. Retina detached. Glioma fills practically whole globe. Choroid normal. Glioma has a spread through coats of eye, and is invading orbit.		
L. A.C. deep. Lying under choroid, and infiltrating both choroid, retina, iris, cil. body, and extending into A.C. is white growth. O.N. much sunken and infiltrated. *Micro.*—Growth v. cellular; contains numerous blood-vessels. Cells large, round. Retina cannot be recognised. Growth infiltrates cornea and sclerotic.	...	February, '01. Left began to go wrong in May, '00. Child taken to Moorfields, where both eyes were said to be getting bad. Now L. much swollen, and A.C. full of yellowish substance. R. similarly affected, but to less degree. 28.2.01. L. enucleation (mass at back of orbit could not be removed).
Section.—Cornea N. A.C. normal. Ditto iris. Vitreous disappeared. Retina replaced by glioma, which fills globe from O.N. to back lens. *Micro.*—Angles obliterated. Lens invaded. Globe full of glioma. Layers of retina cannot be distinguished. Many areæ of degeneration in front. O.N. involved whole length. 5.5.02. Recurrent growth has replaced entirely the normal tissues, except portions of sheath and supporting tissue.		
A.C. good. Iris, cornea, lens, normal. Vitreous has delicate transverse membrane from which white threads pass back to retina. Retina extensively detached, much swollen. Nodules are white in section, with beautiful radiating streaks of hæmorrhages. O.N. looks normal. *Micro.*—A.C. good. Angles blocked. Retina, largely replaced by glioma, much degeneration; endophytic. Choroid infiltrated at posterior pole. O.N. seat of large degenerated mass just behind lamina cribrosa. Infiltrated to cut end.	?	Patient died July.

SUMMARY OF CASES. Royal London

No. of case. Register No.	Name, surgeon, date.	Eye.	Age when growth first noted.	Age at operation.	Duration of life after operation.	Date of first sign of recurrence. Sites of recurrence.	Tension.
39 482	Madelein S. Mr. Lawford's case 24.6.02	L.	?	?	...	...	...
40 494	Peggie de K. Mr. Lang's case ? date	...	...	...	...	...	...
41 541	? name Mr. Sinclair's case 16.5.03	...	...	...	...	...	...
42 542	? name Mr. Maddox's case 20.5.03	...	...	...	...	...	...
43 595	John C. Mr. Lawford's case 6.5.04	...	...	$3\frac{6}{12}$	...	...	...
44 644	Victor A. Mr. Fisher's case 1.2.05	...	...	$1\frac{10}{12}$ yrs.	...	...	...

Ophthalmic Hospital. 1897—1905.

Summary of Curator's Report.	Family history.	Remarks.
Section.—Cornea, A.C., lens, normal. Retina gliomatous—one large growth (7 mm.) at inner part. Shows areæ degeneration. Rest of retina studded everywhere with nodules. Many isolated. Choroid apparently normal. O.N. short; looks healthy. *Micro.*—Glioma with neuro-epithelial rings.		
Micro.—Cornea normal. A.C. good. Iris, lens normal. Tumour, calcareous. Glioma, typical, with neuro-epithelial rings. Shows much degeneration. Covers disc, but does not extend quite as far as lamina cribrosa.		
A.C. angle blocked by peripheral anterior synechia. Iris degenerated; denser than normal. Lens distorted; changes chiefly at Equator. Retina detached; shows nodules of glioma; not far advanced. Glioma cells occur on pigment epithelium. Choroid unaffected.		
Ant. chamber angle blocked by peripheral anterior synechia. One angle contains small mass of glioma. Iris covered with thin layer of glioma. Globe filled. Choroid apparently normal. O.N. swollen; infiltrated for 2 mm.; normal beyond. *Micro.*—A glioma.		
Micro.—A glioma.		
Typical glioma macroscop.		

SUMMARY OF CASES. Royal London

No. of case. Register No.	Name, surgeon, date.	Eye.	Age when growth first noted.	Age at operation.	Duration of life after operation.	Date of first sign of recurrence. Sites of recurrence.	Tension.
45 650	? name Mr. Worth's case 10.2.05	...	...	...	...	...	...
46 652	? name ♀ Mr. Marshall's case 4.2.05	R. + L. Both removed.	...	$\frac{11}{12}$ m.	...	...	...
47 H.R.I. 211 (α)	H. Bolton Mr. Rockliffe's case 3.12.81	L.	First noticed July, '81.	3 yrs.	...	...	T. n.
48 H.R.I. (β)	Rose Addy Mr. Rockliffe's case July, '93	R.	...	4 yrs.	...	...	...
49 H.R.I. 654 O.P.	Alice Blummilt Mr. Rockliffe's case 7.3.05	L.	Mother states from infancy.	$3\frac{1}{2}$ yrs.	...	Recurrent growth noted 12.3.05. Proptosis $\frac{3}{4}$ in. on March 31; exenteration.	T. + ?

Ophthalmic Hospital. 1897—1905.

Summary of Curator's Report.	Family history.	Remarks.
Glioma exo.		
Cornea normal. Iris and corneo-iridic angle normal. Near ora serrata a small gliomatous nodule showing typical necrosis. Nuclei around vessels. Rosettes. Some polymorpho-nuclear invasion. At edge of tumour all retinal elements seem involved. Rods and cones fairly well preserved. No nodules in optic nerve. *Second Eye.*—Tumour, similar type; shows great thickening of ganglion cell layer on approaching tumour.	...	One eye collapsed, being opened for diagnostic purposes.
Report by Mr. T. D. Marshall. Retina and vitreous full of small round gliomatous cells and neurogleial elements. O.N. appears healthy.	?	No recurrence. Child healthy, 1898, when last seen.
Report by Mr. Collins.	...	No recurrence. Child healthy, 1899.
L. globe (*Sagittal Section*). A.C. fairly deep. Pupil dilated. Post. synechiæ and angle blocked. Nerve appears thickened and infiltrated. Vitreous shrunken. Retina detached. Large sub-retinal exudates containing hæmorrhage. Large tumour occupies whole of posterior half of globe. Contains large vessels with gelatinous-looking sheaths. Nerve involved. *Micro.*—Tumour a glioma; occupies posterior half of globe. Brown colour due to hæmorrhages. Much necrosis. Vessels have sheaths of well stained cells. No rosettes. Reaches back of iris. Choroid extensively involved; optic N. involved. Has broken through especially at side of nerve. Dural nerve can be distinguished. Extra-ocular growth, less necrosis.	...	History. Child ran against perambulator, Nov. '04. Damaged L. eye. Gradual proptosis from this date. However, mother admits eye always looked glassy and different from other. *Under chloroform.*—Eye proptosed. In a central position, ¾ in. in front of cil. margin, somewhat distended with engorged scleral vessels. No chemosis or pink zone. Corneal haze. A.C. shallow. Iris discoloured. Pupil dilated with green reflex. Large solid mass to be felt to inner side of orbit posterior to globe, and the whole of the contents at this posi-

SUMMARY OF CASES. Royal London

No. of case. Register No.	Name, surgeon, date.	Eye.	Age when growth first noted.	Age at operation.	Duration of life after operation.	Date of first sign of recurrence. Sites of recurrence.	Tension.
49 H.R.I. 654 O.P.	Alice Blummilt —*continued.*						
50 657 O.P.	♀ Mr. Parson's case March, '05	L.	...	...	...	...	...

Ophthalmic Hospital. 1897—1905.

Summary of Curator's Report.	Family history.	Remarks.
Sagittal Section. Cornea, A.C., iris normal. Lens *in situ.* Typical glioma exo. Choroid invaded in region of papilla. Free end of nerve seems uninvolved. Sclera seems intact. *Micro.*—Corneo-iridic angle blocked both sides. Iris cellular; cil. body normal. Retina totally detached; reaches close up to lens. Except for a short distance at ora serrata whole retina has undergone gliomatous degeneration. Tumour of usual type with much necrosis in anter. parts. True rosettes. Choroid involved in region of papilla. Scattered nodules also on surface. Pigment epithelium sometimes destroyed. Nerve head involved, and a few small nodules outside lam. cribrosa. Nerve at cut surface seems quite free. No evidence of extra-ocular growths.		tion were matted together. Growth appeared to be perforating sclerotic at posterior portion and surrounding optic N. R.E. apparently normal.

PAPILLOMA LIMBI CONJUNCTIVÆ.

By C. Paschefff, M.D. (Sofia, Bulgaria).

Primary papilloma of the conjunctival limbus, judging from the scarcity of recorded cases, seems to be very rare. During the six years of my ophthalmic practice in the Alexander Hospital in Sofia, I have observed four cases of this affection. In the present paper I shall record them shortly, and briefly review all the cases at present published.

Case 1.—A man, 56 years old, a farmer, in good health, had remarked for 15 days a small growth on his left eye. He had had no previous inflammation whatever in that eye.

Status Præsens.—The growth is situated on the nasal side of the limbus, and involves the conjunctiva more than the cornea. It is horizontally elongated like a pterygium, about 0·5 cm. in length, more prominent towards the cornea than towards the conjunctiva, and quite distinct from the latter, which is thickened and much injected around. It adheres to the cornea for about 1½ mm., and has an extensive greyish edge. The growth, which in its middle attains a height of about 3 mm., is of a reddish-grey colour, with an irregular, strawberry-like surface. It is firmly attached to the cornea, and slightly movable with the conjunctiva over the sclerotic. The conjunctiva is normal elsewhere. The left preauricular gland is not enlarged.

The tumour was removed like a pterygium, and the edges of the wound sutured. As soon as the attachment of the tumour to the cornea was divided, the whole growth could be easily moved on the sclerotic. During the operation there was more hæmorrhage than in the excision of an ordinary pterygium.

Microscopical Examination.—The tumour was fixed and hardened in alcohol, and embedded in celloidin. The sections were stained with hæmatoxylin, hæmatoxylin-eosin, v. Gieson, picrocarmine, and Wiegert's elastic tissue stain.

The microscopical examination gives the following result:—(Figs. 1 and 3, Pl. VII, represent a section perpendicular to the

surface of the papilloma.) The fibrous layer of the conjunctiva near the growth, and especially under it, is much thickened and vascularised. The vessels are not only increased in number, but are greatly dilated, full of blood, and with thickened walls, especially the veins. Under them many elastic fibres closely pressed together are seen.

The adenoid layer is more distinct than normally; its fibres are loosened and separated by numerous small vessels and infiltrations of lymphocytes and mono- and poly-nuclear leucocytes. From this layer many connective tissue bundles with small thin blood vessels, consisting mostly of an endothelial wall, arise, and proceed upwards towards the epithelium. Some of these stems of connective tissue, before reaching the epithelium, divide like the branches of a tree into two or three other similar stems. All these branches and stems are covered with an extremely thickened stratified epithelium, thus constituting many *papillæ* of various sizes.

The epithelial cells which are in immediate contact with the connective tissue are cylindrical, short, and undergoing active proliferation. They rest upon a distinct thin membrane formed of a few fine, compressed, connective tissue fibres. Towards the periphery the epithelial cells become more polygonal and flatter. Some of them look swollen, are deprived of their nuclei, and stain very faintly. On the surface the cells are quite flat; some have lost their nuclei, but there is nowhere any actual cornification. These cells remind one very much of those which are met with in spring catarrh covering the nodular growths around the limbus.

The epithelium of the papillæ is almost everywhere much more developed than the connective tissue. The latter is infiltrated with numerous lymphocytes and leucocytes, some of which are even seen scattered in the epithelium of the papillæ. The epithelium, even where it is thickest, shows no cystic degeneration or epithelial pearls.

The corneal edge of the tumour (fig. 1) ends in a point, and shows clearly how the vascular connective tissue of the future papillæ invades the thickened, stratified epithelium covering it, and at some places begins to raise it. At the extreme edge the peripheral epithelium is somewhat swollen, and gradually passes

into the normal corneal epithelium. At the opposite edge of the tumour, towards the conjunctiva, the epithelium also passes into the normal conjunctival epithelium through a series of small undulations of varying thicknesses of epithelium, constituting what are called the "normal papillæ" of the conjunctival limbus.

Similar to this case are those published by Ayres (1), Norris (2), Sims (3), Goggin (4), and Grunert (5). In these the papilloma was much more developed, and was seated with a large base on the conjunctiva and cornea. In one instance it covered the whole of the latter (Ayres), and in another (Sims, Case 2) it stopped at the limbus, and instead of invading the cornea, overlapped it to the extent of 2½ mm. The histological structure in all of them was more or less the same; once only a horny layer was observed covering the papillæ (Grunert, Case 3).

Some of the patients have suffered previously from conjunctivitis, and most of them were farmers. After the operation the growth has recurred in some instances. It was three times operated upon for recurrence in the case of Goggin.

Case 2.—A man, 30 years old, in good health, had noticed, 4 months before he was seen, a small growth on his left eye. It had increased very little since then. He had had no inflammation of the conjunctiva of that eye.

Status Præsens.—The little tumour is situated just at the centre of the limbus on its inner side, and with its long axis perpendicular to it. It is seated more on the conjunctiva than on the cornea, is horizontally elongated, and has distinct edges—overlapping both the cornea and the conjunctiva. It is firmly attached to the limbus by a short, slightly pedunculated base. Its length is about 4½ mm., its greatest breadth 2 mm., and its surface is rough and of a rose-white colour. The conjunctiva around it is somewhat thickened, and with many blood vessels running towards the base of the tumour. Elsewhere it is normal. The whole growth is slightly movable with the conjunctiva over the sclerotic.

The tumour was easily detached from the limbus, leaving a bleeding spot which was touched with the galvanocautery.

Microscopical Examination.—(Fig. 2, Pl. VII, and Fig. 1, Pl. VIII, show a section perpendicular to the surface.) This growth is essentially a much thickened epithelial plaque, with distinct closely-set papillary formations in its base.

The epithelium is very regularly stratified, and covered on the surface by a thick layer of perfectly flat epithelial cells. The papillæ, although distinct and separate at the base, are almost uniformly united at the surface by the thickened, stratified epithelium. They are formed in the same way as in Case 1, and are infiltrated with many lymphocytes and leucocytes which invade their connective tissue and are seen also in their epithelial covering. The growth, having a broad, slightly pedunculated base, does not show so clearly as in Case 1 its true relations to the conjunctiva or the cornea.

On the surface of the tumour no distinct papillæ are seen, but rather undulations, except that near the cornea there is some indentation of the surface and a more truly papillary arrangement. Some of the superficial flat cells just in the middle of the section seem swollen, loosened, and even detached from the surface (Fig. 1, Pl. VIII).

A case published by Roche [6] was much more developed than this one, especially in height, and it had a more distinct peduncle. It was pyramidal in form, attached to the limbus by a short peduncle, and overlapped the cornea and still more the conjunctiva.

In the histological structure of the papillæ and in the relation between them this case resembles closely that described by Grunert (Case 3), in which the epithelial layer was thick and the papillæ so close together that one could not distinguish the exact limits between them. But it differed from the present instance in being covered on the surface by a horny layer.

Case 3.—A farmer, 55 years old, consulted me for a growth on the left cornea. It had begun 6 months previously like a

small grain on the inner margin of the cornea, and had been constantly growing towards the pupil.

Status Præsens.—The inner half and centre of the cornea are covered by a growth of a greyish-rose colour, and irregular mulberry like surface. It has the form of an isoceles triangle with the point covering the inner half of the pupillary area, and with the base directed towards the limbus. The base is a little concave towards the latter so that it touches it with its extreme points only, leaving thus a very narrow, slightly bi-convex space, within which the corneal surface has a greyish appearance and is markedly dull. The tumour is 6 mm. long, 3 mm. high, and 5 mm. wide at the base, where it arises almost perpendicularly above the conjunctiva. The latter all round the tumour is thickened, of a wine red colour, and deeply injected with numerous vessels which run towards the growth. The point of the tumour, occupying the pupillary area of the cornea, is also distinctly raised above the corneal surface, and is surrounded by a narrow band of thickened, greyish-coloured epithelium. The rest of the cornea and conjunctiva is normal.

The tumour was removed with the keratome from the surface of the cornea. There was considerable bleeding, especially towards the limbus. It was detached from the latter easily, and did not show any great adhesion to the conjunctiva. The corneal tissue on examination with the magnifier was sufficiently transparent, even near the affected limbus, to permit one to see a few deep centripetal blood vessels coming from the limbus and running in parallel lines in its substance. The wound was cauterised and healed completely in 3 weeks. The patient left the hospital with a superficial, fairly transparent opacity of the cornea in the former position of the growth.

Microscopical Examination.—The tumour was fixed in formol and hardened in alcohol; the sections were stained with hæmatoxylin, hæmatoxylin-eosin, picrocarmine and v. Gieson.

It is found to consist of numerous irregular papillæ of varying size, of which the epithelial elements are considerably more developed than the connective tissue (Fig. 2, Pl. VIII) represents a section of the advancing corneal edge of the tumour perpendicular to its surface. There is everywhere a distinct limiting membrane between the connective tissue and the basal

epithelial cells. The latter are cylindrical and longer than in the previous cases; they are set perpendicularly upon the membrane. On the surface the epithelial cells are quite flat, stain less than the others, but are provided with nuclei.

Bowman's membrane seems to be destroyed and absent especially towards the limbus. It is replaced by a fibrous tissue from which small stems with very thin-walled blood vessels arise, to form the axes of the papillæ. This connective tissue, rather poor in vessels, is infiltrated with many lymphocytes and leucocytes which are seen even among the epithelial cells. Fig. 2, which corresponds to the advancing edge of the tumour, shows cells similar in form to those of the deepest layer of the corneal epithelium—cylindrical, elongated and closely set. They stand upon the membrane, which can be traced underneath the neighbouring papilla and also upwards into its axis.

CASE 4.—A woman, 50 years old, in good health, and without any history of previous inflammation of the eyes, had remarked 3 years previously a small growth on the temporal side of her right cornea. Since then it had grown constantly, and had covered the pupil, depriving her of sight in that eye. It was not painful and she had tried several times to get rid of it by tearing it off with her finger nails. Lately it had grown so much that she could no longer close the eye.

Status Præsens.—The growth covers almost the whole of the cornea with the exception of a small part of its supero-internal quadrant. It is of a rose-grey colour; its surface is cauliflower-like and it bleeds very easily. By its base it adheres very firmly to the cornea, and it is limited everywhere by the limbus, which is overlapped by its flattened peripheral edge. At its centre it is very much elevated above the corneal surface—about $1\frac{1}{2}$ cm.; so that it pushes forward the upper lid and has very much the aspect of a sessile mushroom. It seems to be made up of four lobes closely pressed upon one another. The conjunctiva around the tumour is somewhat thickened, vascularised and with much enlarged veins all running towards the base of the tumour. There was good perception of light.

The growth was removed and the surface cauterised. The patient left the hospital with vision = 4/50.

Microscopical Examination.—The growth consists of a number

of long thick well developed papillæ, with large vessels full of blood and very little connective tissue. The epithelium of the papillæ is very thick and stratified; its basal cells are in active proliferation, while the superficial are, in most of the papillæ, swollen and with badly stained or altogether absent nuclei [7].

This case resembles very much that given in the excellent work of Lagrange on the tumours of the eye (Vol. I, Pl. VI, Figs. 3 and 4), and for this reason I have abstained from illustrating it.

Along with these two cases may be reckoned all those which have begun either directly in connection with the limbus or merely in contact with it. These have been described by most authors as "papilloma of the cornea." Such are the cases of Professor Gayet [8], Lagrange [9], Démichéri [10], and Magnus [11]. Even the case of Dean [12] may be classified here, since the history which the patient gives in regard to the relation of the tumour to the limbus is of no decisive importance. Further even where there is some corneal epithelium separating the tumour from the limbus, it always presents changes which cannot be seen with the naked eye (Case 3).

From the study of all these cases we may make the following deductions with regard to the clinical, anatomico-pathological and etiological features of this peculiar and rare affection of the limbus.

Clinically the papilloma has more or less of a mulberry-like surface, which may become cauliflower like, especially on the cornea (Case 4). It develops rather quickly—from some weeks to several months—and very frequently recurs after operation. It is generally superficial and benignant, although it is said that it may degenerate into an epithelioma (Lagrange). Its colour is pale rose or reddish grey, approaching the colour of the fully formed palpebral papilla of spring catarrh. It appears at all ages; the youngest patient observed was 12 years old, and the oldest 71. It has usually been met with on one eye, and has only once appeared on both (Magnus).

As to its situation three types of *primary papilloma of the limbus* may be distinguished.

To the first type belong all those cases in which the papilloma begins on the conjunctiva and spreads towards the limbus and cornea. It begins anywhere on the conjunctiva around the limbus, and generally within a zone not wider than 4—5 mm. from it. It is always sharply limited towards the conjunctiva, and its peculiar feature is its advance towards the limbus and cornea, which it may entirely cover. Sometimes, however, it stops at its margin and if it still continues to grow, it overlaps it but does not invade it.

To the second type belong those cases which spring from the limbus itself, but instead of invading the cornea become pedunculated and grow in height rather than superficially. Some of these cases take on a pyramidal form and overlap with a large base both the cornea and the conjunctiva.

Under the third type is included the papilloma which begins at the limbus and develops entirely on the cornea. Here the epithelial part of the papilla is furnished by the cornea, but the vasculo-connective tissue comes entirely from the conjunctiva. The growth may cover the entire cornea but is always sharply delimited by the limbus, and has never been seen to invade the conjunctiva proper.

Histologically, the papillæ are of different degrees of development, single or ramified, but always of the same structure. In all the epithelial element is the predominant one, and is furnished by the conjunctiva or cornea according to the anatomical situation of the papilloma. Sometimes it is so hypertrophied that the papillæ are pressed together and on the surface of the papilloma one cannot distinguish the exact limits between them. In almost all cases the superficial cells are flat but not really cornified.

The connective tissue seems to be more abundant in the first and second types than in the third. In the latter it may be represented by a few fibres only which sustain the large well-developed blood vessels (Case 4). But in all these types the connective tissue is the same, coming mostly from

the adenoid layer of the conjunctiva. At the beginning of the corneal invasion it seems to advance between the epithelium which is already thickened and stratified and Bowman's membrane. Later, however, the latter is generally destroyed, but the cornea is never infiltrated by the epithelium, and clears up after the removal of the growth (Case 4).

In most instances the papillæ are infiltrated more or less with lympho- and leuco-cytes, which seem to furnish evidence of a previous inflammation.

As to the *etiology* of papilloma of the limbus, little can be said, except that in many cases a previous irritation or inflammation of the conjunctiva has been observed. In favour of this as a cause, the lymphoid infiltration of the papillæ may also be mentioned, and the fact that papillomata are usually met with in farmers and people exposed to ocular irritation. This, however, does not prove that they are always of an inflammatory nature.

The papillæ which are found normally on the conjunctiva near the limbus have generally nothing to do with the pathogeny of papilloma, for the latter may appear anywhere on the conjunctiva, as well as on other parts of the body where there are no papillæ [13, 14].

The interpretation which Goggin gives of his case, namely, that it was a simple hypertrophy of the epidermis and papillary layers of the conjunctiva, seems to me unsatisfactory, since his case is just the one in which the papilloma recurred the most frequently.

Of the four cases which I have reported here, perhaps the first seems the most closely connected with previous conjunctival inflammation, since it showed the greatest infiltration with lymphocytes, and the relation between the normal conjunctival epithelium and that of the papilloma seemed to be that of a *gradual* thickening and stratification.

In all other cases the papilloma remains a *special and definite tumour*, which may be influenced in its appearance by an exterior influence, but cannot be caused by it unless there is a special predisposition of the tissues to it. This

explains also its rarety, not only at the limbus, but also elsewhere on the conjunctiva.

In conclusion, I have to thank Mr. Coats for the photographs of my sections with which this article is illustrated.

References.

(1). Ayres. Papilloma of the Cornea. Ophthalm. Rev., 1891, p. 257.
(2.) Norris. Recurrent Papilloma of the Sclero-Corneal Junction. Trans. Amer. Ophthalm. Soc., 1874, p. 549.
(3.) Sims. Two Cases of Papilloma of the Conjunctiva encroaching upon the Cornea. Arch. of Ophthalm., 1892, vol. xxi, p. 91.
(4.) Goggin. Papilloma in the Sclero-Corneal Region. Arch. of Ophthalmol., 1894, vol. xxxiii, p. 22.
(5.) Grunert. 5 Fälle v. Papilloma der Bindehaut. Zehend. klin. Monatsblätt. f. Augenheilkunde, 1889, vol. 37, p. 111.
(6.) Roche. Un Cas de Papillome du Limbe de la Cornée. Annales d'Oculistique, 1901, vol. 125, p. 267.
(7.) Pascheff. Papillome Limbo-Cornéen. La Clinique Ophtalm- 10 Mai 1904 (Contribution à l'Étude des Tumeurs de l'Œil).
(8.) Gayet. Lyon Medical, 1879.
(9.) Lagrange. Traité des Tumeurs de l'Œil, vol. i, 1904; Tumeurs Primitive de la Cornée. Arch. d'Ophtal., 1899, vol. xix, Avril.
(10.) Démichéri. Papillome de la Cornée. Arch. d'Ophtalm., 1899, vol. xix, p. 561.
(11.) Magnus. Ein Fall von Papilloma Conjunctivae. Klin. Monatsbl. f. Augenheilkunde, 1887, vol. xxv, p. 384.
(12.) Dean. A Case of Primary Papilloma of the Cornea. Trans. Ophthalm. Soc. of the United Kingdom, 1903, p. 31.
(13.) Virchow. Pathologie des Tumeurs, vol. i, p. 331.
(14.) Cornil and Ranvier. Manual of Pathological Histology, vol. i, p. 281.
(15.) Velhagen. Ueber Papillombildung auf der Conjunctiva. Sammlung zwangloser Abhandlungen aus dem Gebiete der Augenheilk. v. Prof. Vossius, vol. v, part 7, 1904.
(16.) Saemisch. Das Papillom der Bindehaut. Graefe-Saemisch, Handbuch der Gesamten Augenheilkunde, vol. v, part 1, p. 672, 1904.

Description of Plates VII and VIII.

Plate VII.

Fig. 1, × 10.—General view of the papilloma from Case 1. The corneal edge is to the right.

Fig. 2, × 10.—General view of the papilloma from Case 2. The corneal edge is to the right.

FIG. 3, × 100.—High power view of one of the papillæ from Case 1. It consists of a central branching stem of vascular connective tissue, moderately infiltrated with lymphocytes and leucocytes. These are also found among the epithelium, especially in its deeper layers. The epithelium is greatly thickened, and its cells become flattened towards the surface and frequently lose their nuclei. There is, however, no true cornification.

PLATE VIII.

FIG. 1, × 100.—High power view of the tumour in Case 2. The connective tissue stems are small, single, and do not branch. The spaces between them are entirely filled in with epithelium, so that the surface of the tumour is not papillated, but smooth. The amount of epithelium greatly exceeds the amount of connective tissue. Some of the superficial cells are swollen and detached, but the nuclei are well stained quite up to the surface; there is no cornification. Both the epithelium and the connective tissue are infiltrated with lymphocytes and leucocytes.

FIG. 2, × 100.—Section of the central edge of the tumour in Case 3. The epithelium greatly preponderates over the connective tissue. Both are slightly infiltrated with lymphocytes and leucocytes. The thin line below represents a part of Bowman's membrane; a few fibres from this could be traced in some of the sections running up into the connective tissue of the papillæ to form a basement membrane for the epithelium, but this is not shown in the present section.

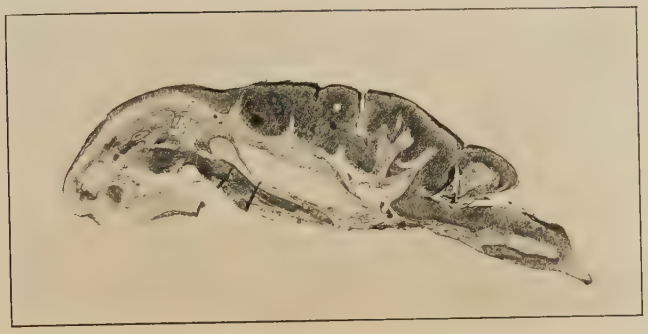

Fig. 1.

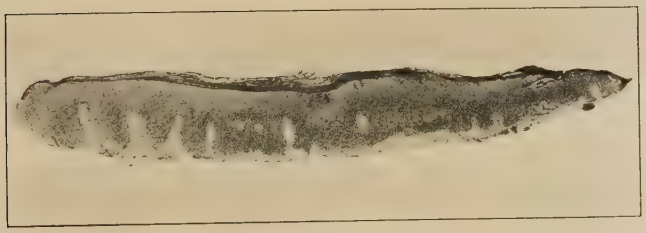

Fig. 2.

Fig. 3.

Bale & Danielsson, Ltd.

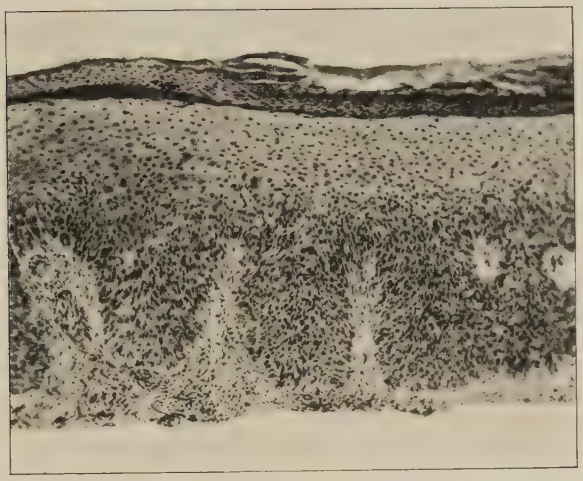

Fig. 1.

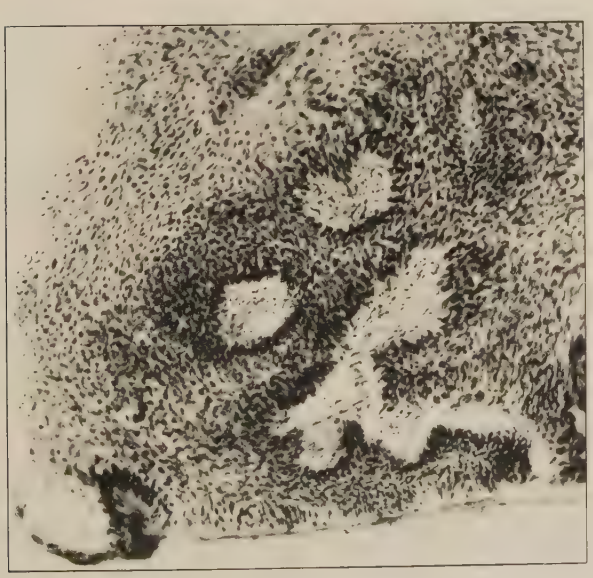

Fig. 2.

Bale & Danielsson, Ltd.

A CASE OF TUBERCLE OF THE NERVE HEAD.

By George Coats (Curator).

Harold J., æt. 1 year and 4 months, attended the out-patient department of the R.L.O. Hospital on January 21st, 1905, under the care of Mr. Fisher. The left eye was said to have squinted and to have become "dimmer" during the previous three weeks. The cornea was dull; there was slight pericorneal congestion; the pupil was large and eccentric, and there were posterior synechiæ downwards and inwards. The tension was thought to be somewhat full, but the eyeball was tender, and the baby cried when pressure was exercised upon it. No view of the fundus could be obtained. In-patient treatment was at first refused by the parents, but a week later the child was admitted. He was, however, found to be very ill, with rapid breathing and a temperature of 102° F. Arrangements were therefore made for his transference to Great Ormond Street Hospital, where he was admitted under the care of Dr. Voelcker, to whom I am indebted for the use of the following notes.

The child had measles 10 weeks ago, and has been ill ever since. He has never been free from cough; there has been wasting, and the motions have been offensive. During three weeks he has been restless, and for the past fortnight he has been putting his hand to his ear as if in pain. The child was breast-fed until three weeks ago.

He is the last of 8 children; the first 4 were still-born, and there has been one miscarriage; the 7th died at the age of 3½ years from empyema. The mother's father died of phthisis.

On admission there was right facial palsy. The right side of the chest showed impaired movement, and the apex was dull to percussion back and front. In the same situation there was tubular breathing, and there were crepitations in the lower part of the right lung. On January 30th he had a convulsion: both sides of the face twitched, especially the upper parts; the arms

and legs were flaccid; the eyes were turned to the right, and then there were movements of the head to the right; there was no incontinence. Later there were two other fits, and the child died on January 31st.

Post-mortem Notes (30 hours after death).—The lungs showed every stage of tuberculous invasion from miliary tubercles up to large walled cavities containing partially evacuated pus. There was tubercle of the larynx and of the bronchi, but without perforation. The intrathoracic glands were caseous and softened, equally on the two sides. Abdomen.—Tubercles in the liver, spleen, and kidneys. In the intestines, ulcers and miliary tubercles. Caseous mesenteric glands. Head.—There was a caseous patch at the left occipital pole on its ventral surface, and spreading upwards from this over the cortex and into the fissure of Sylvius; the dura was adherent to it, but there was no general tuberculous meningitis, as the right side was normal. Pus in the middle ear. The left eye was removed for examination; the right was not kept.

Pathological Examination of the Left Eye.

The globe was hardened in formol, frozen, bisected sagittally, one half embedded in celloidin, and cut in serial section.

Macroscopic Examination.—The anterior chamber is fairly deep. The corneo-iridic angle is blocked above; below it seems to be free, and on this side there is an adhesion of the iris to the lens capsule. The lens is *in situ*, and the vitreous clear. The retina is detached from the papilla to the ora serrata by a milky exudate. The optic nerve head is occupied by a yellow mass situated partly inside, partly outside the lamina cribrosa (Pl. V, Fig. 3). The intraocular part is quadrangular in shape, and measures 4·5 mm. in breadth by 3·5 mm. in height; the retina comes off from its anterior angles. Posteriorly, it overlaps the choroid for some distance without being adherent to it. The extraocular part is connected with the foregoing by a narrow neck, in the situation of the porus opticus. It measures 4·5 mm. longitudinally and 3 mm. transversely, and ends above with a well-defined rounded border. The nerve sheaths are distended where it is situated, and there are no isolated nodules. Around the nerve entrance

the choroid is only slightly thickened, and for a very short distance, and in no part of the uvea are there any visible nodules.

Microscopic Examination.—The cornea is normal. The corneo-iridic angle is blocked on both sides; above, the adhesion reaches as far forward as the membrane of Descemet, and the iris forms an acute angle with the cornea; its root is somewhat atrophic, its stroma cellular; there is ectropium uveæ; posterior synechiæ are not present. Below, the adhesion does not reach so far forward. The angle is rounded and filled in with new-formed connective tissue; the pupillary border is adherent to the lens capsule by connective tissue, and there has been some dragging at the corneo-iridic angle. The iris on this side is also infiltrated. There is therefore evidence of a plastic iritis, but there is no evidence histologically that it was of tuberculous origin—there are no giant cell systems or epithelioid cells. The retina is detached and much folded; its nuclear layers are well preserved, but there is a good deal of œdema of the inner layers. The rods and cones are very imperfectly preserved. The retinal vessels are full of blood; their walls stain very badly, and seem to be necrotic even far out into the periphery of the retina. In the subretinal exudate there are many groups of cells; they have large, pale, swollen bodies and small nuclei, and sometimes they contain a few spicules of pigment. They are probably swollen hexagonal pigment cells and leucocytes. Similar groups of cells are found in the anterior part of the vitreous. The lens and ciliary body are normal.

The mass in the nerve head (Pl. IX, Fig. 1) is a granuloma. There are no perfectly typical tubercle systems in it, but there are a few giant cells of the Langhans type. For the most part it consists of round and spindle-shaped cells. Blood vessels are very scanty, and where they occur show much narrowing of their lumina from endothelial proliferation and thickening of their walls. There is a good deal of caseation in the extraocular part, while the intraocular part is entirely necrotic except that it is lined at the sides by a thin layer of degenerated retinal tissue which retains its nuclear staining. Immediately above the mass the central vessels are normal; in the necrotic intraocular portion the vessels are also necrotic, and, as mentioned, they remain so for a long way out into the periphery. Where it passes through

the porus opticus the mass is much constricted, and the lamina cribrosa has been destroyed. The pia-arachnoid is slightly infiltrated, and there are a few small nodules on the inner surface of the dura near the globe; but the sheaths are mostly normal, the tissue has not been growing freely up the vaginal space. The nerve above the main mass is a little infiltrated and atrophic, but there are no isolated nodules in it.

The choroid is only involved for a very short distance round the nerve head—not more than a papilla diameter. It has evidently been secondarily invaded from the mass in the nerve. There is, on the whole, less caseation in the choroidal portion, and a few tolerably well-formed tubercle systems are found in it (Pl. IX, Fig. 2). A little distance from the papilla the infiltration ceases, and the rest of the choroid is empty of blood and condensed, but apparently normal. Tubercle bacilli were found in the mass in the nerve, but very scantily. Inoculation experiments could not be carried out, as the eye had already been hardened before the nodule was discovered.

The case belongs to a decidedly rare but fairly well-defined group—conglomerate tubercle of the nerve head. The histological characters of the mass itself were not absolutely characteristic, and might have supported a diagnosis of gumma, especially in view of the marked sclerosis of the vessels; and the finding of a very few giant cells would not have invalidated this diagnosis. But the discovery of tubercle systems in the better preserved tissues of the choroid immediately adjacent to the nerve, the finding of tubercle bacilli, and the clinical and *post-mortem* aspects of the case all place the diagnosis beyond dispute.

It differs from most of those on record in that the mass in the nerve head was the only one in the eye. Most other cases have had other nodules either in the retina or somewhere in the uvea. Iritis was indeed present, but it was an ordinary plastic iritis with no specific characters. It was apparently produced by tubercular toxines originating in the mass behind, and the case therefore raises interesting questions as to whether a simple iritis might be produced by

similar toxines circulating in the blood, without any other local lesion in the eye; that is whether in a tuberculous subject an iritis might be set up without any local settlement of tubercle bacilli. The supposition has been both asserted (Bürstenbinder) and denied. It has been maintained that in these cases nodules are always present, but so small as to escape clinical observation. In the present instance, however, the eye was examined in serial section, and they were quite absent.

The case in the literature which most nearly resembles the present one is that of Arnold Knapp. In a child aged 2, a white reflex had been noted from the pupil of the left eye which was divergent. The media were clear, the tension was normal, and there was no iritis. The retina was totally detached, and its vessels were visible on focal illumination. The eye was excised on suspicion of glioma. In the nerve head a mass was found extending back into the nerve with a sharply defined outline, and consisting of typical tuberculous tissue. Its intraocular portion was bounded laterally by the retina, which came off from its anterior angles, and was detached up to the ora serrata. There were two nodules in the choroid more anteriorly. Tubercle bacilli were found. No other evidence of tuberculosis was discovered at the time of operation, but a year later there was tuberculous disease of both elbow joints, cough, and hectic fever; there was no meningitis.

Spalding has also reported a case. A boy, aged 8, had symptoms resembling those of meningitis—rigors, headache, vomiting, retraction of the head, and apathy. Ten days later a yellow reflex was noticed from the left pupil; there were swelling of the upper lid, deep congestion of the globe, posterior synechiæ, discoloration of the iris, and ophthalmoscopically a yellow tumour in the vitreous, over which the retinal vessels could be seen to course. Enucleation of the eye was followed by relief of all the symptoms. The vitreous was one-third filled with a firm yellowish tumour arising from the optic papilla, more from its circumference

than its centre. Microscopically it consisted of necrotic tissue, small cell infiltration and giant cells. There was a funnel-shaped detachment of the retina. Tubercle bacilli were found.

A case of O'Sullivan and Story also closely resembles the present one, except that there was extensive involvement of the retina. A woman, aged 21, was seen 3 months after loss of vision in the right eye. There was a large white swelling in the region of the disc, with white spots about the macula. The eye was enucleated 3 months later. There was a mass around the nerve entrance 1/3 inch broad by 1/5 inch high, much like the one described above, according to the picture. It consisted of typical tuberculous tissue with caseation, and there were similar tuberculous nodules in the retina, which was detached. The patient was well 18 months later, except that she had been losing flesh and had pains in the back of the head. No tuberculous lesion could be discovered, however. Apparently the retina may be involved without the nerve, as in a case published by Hancock in the last number of these Reports, where also other similar instances are mentioned.

A case reported by Weiss belongs to the same category, but there was extensive tuberculous disease elsewhere in the eye. A man, aged 51, developed pain and lachrymation in the left eye shortly after an attack of pneumonia. There was peripheral corneal ulceration and iritis, with subsequent development of nodules. Later the sclera became staphylomatous, and the eye was enucleated 2½ months from the onset of symptoms. In the nerve head there was a mass 6 mm. broad by 2 to 3 mm. high. It contained typical tubercles with giant cells, and these were also found in the course of the nerve through the scleral canal, but not outside. There were some nodules in the retina peripherally, and in the iris and ciliary body. The choroid was generally infiltrated, but showed no tubercles. There was no evidence of general tuberculosis.

Brailey's case is probably of the same kind. A boy, aged 2, had some degree of buphthalmos, a deep anterior

chamber, posterior synechiæ, and what appeared to be a detached retina. The tension was raised. Projecting from the region of the papilla there was a mass the size of a large pea, which pushed back the lamina but did not extend beyond it. It contained typical tubercle systems. The choroid in the immediate vicinity was much thickened by similar tissue which tapered off rapidly into unaffected choroid. There were a few patches in the adjacent sclera. Brailey inclines to think, on the ground of general experience, that the original focus was in the choroid, but points out that the main mass was in the nerve, and that the choroid was only involved in its immediate vicinity.

Less typical are two cases of Michel's. In one the retina was extensively involved, and there were also tubercles in the nerve head. In the other there were two isolated tuberculous nodules in the region of the lamina. In a case of Sattler's also the main focus was outside the lamina, but the intraocular portion of the nerve was also involved, and there were miliary nodules in the retina. There was extensive tuberculous disease of the orbit, and the child died 5 months later of tuberculous meningitis. A nodule was found *post-mortem* in the chiasma, and there were tuberculous bronchial glands. Kabsch has also reported a case with tubercles in the region of the lamina. A case of Emanuel's presents a superficial resemblance to the others, but has evidently originated in the choroid.

These are all the cases which I have been able to find in the literature, so that the condition is evidently a rare one.

References.

Brailey. Trans. Ophth. Soc., vol. iii, p. 129, 1882–83.

Bürstenbinder. Arch. f. Ophth., vol. xli, pt. 1, p. 85, 1895.

Emanuel. Klin. Monatsbl. f. Augenh., vol. xl, p. 210, 1902.

Kabsch. Ueber Scheidenerkrankungen d. Sehnerv. Inaug. Diss., Würzburg, 1882.

Knapp, Arnold. Arch. f. Ophth., vol. xxxii, p. 22, 1903.

Michel. Münch. Med. Wochensch., p. 7, 1903.

O'Sullivan and Story. Trans. Roy. Academy of Med. in Ireland, vol. xvii, p. 451, 1899.

SATTLER. Arch. f. Ophth., vol. xxiv, pt. 3, p. 127, 1878; and Beilageheft z. Centralbl. f. prakt. Augenheilk., p. 9, 1877.
SPALDING. Trans. Amer. Ophth. Soc., vol. x, pt. 1, p. 141, 1903.
WEISS. Arch. f. Ophth., vol. xxiii, pt. 4, p. 141, 1877.

DESCRIPTION OF PLATE V, FIG. 3, AND PLATE IX.

PLATE V.

FIG. 3.—Macroscopic view of the eye to show the mass in the nerve head and the detachment of the retina by a milky exudate.

PLATE IX.

FIG. 1, × 9.—The mass in the nerve head. The intra- and extra-ocular portions are connected through the scleral canal by a narrow neck, and in this situation the lamina cribrosa has disappeared. The intraocular part is quadrangular, and is entirely necrotic except for a narrow rim of degenerated retinal tissue laterally. The retina comes off from the anterior angles and is detached. The extraocular part ends in a well-defined wavy line; it is much less caseous than the intraocular portion. The sheaths of the nerve are very little infiltrated, and show no tuberculous nodules. The choroid is only slightly involved, and for a very short distance around the nerve entrance.

FIG. 2, × 200.—A tubercle system in the choroid close to the nerve entrance. It shows round-cell infiltration, epithelioid cells, a giant cell of the Langhans type, and slight caseation near it.

Fig. 1.

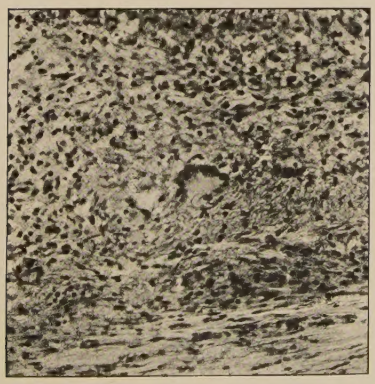

Fig. 2.

Bale & Danielsson, Ltd.